

---

# **CLINICAL CASES**



---

Case: Mrs. BL



# Mrs. BL: Profile

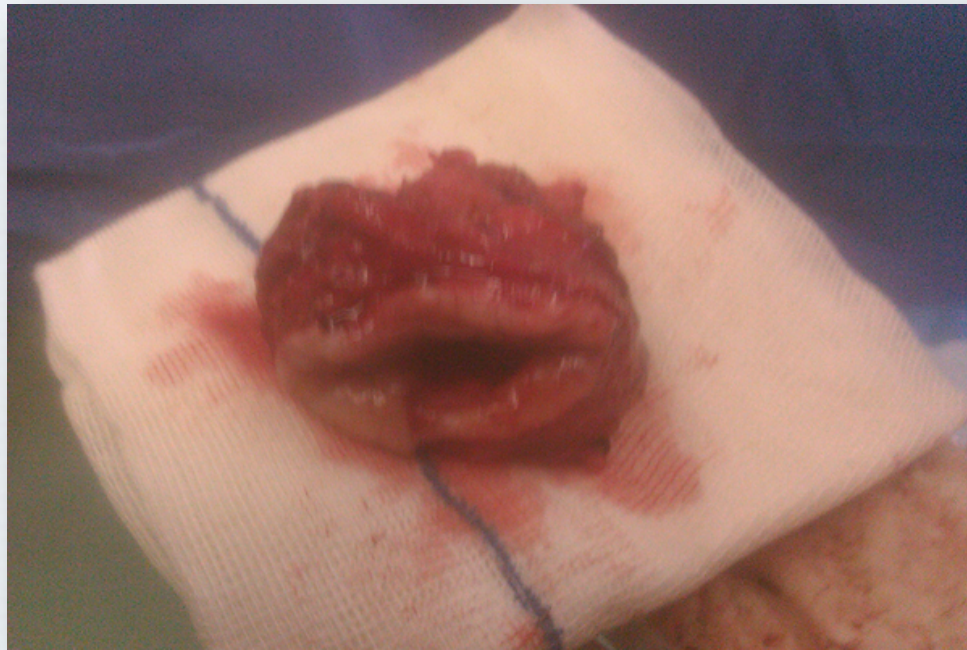---

- 31-year-old female, office clerk
- Two pregnancies, two live births
- Routine gynaecological examination
- No symptoms of any disease
- No medical history
- No medication

# Mrs. BL: Findings

---

- Carcinoma of cervix in situ treated via cone biopsy
- Subsequently asymptomatic for 8 years



# Mrs. BL: Subsequent History

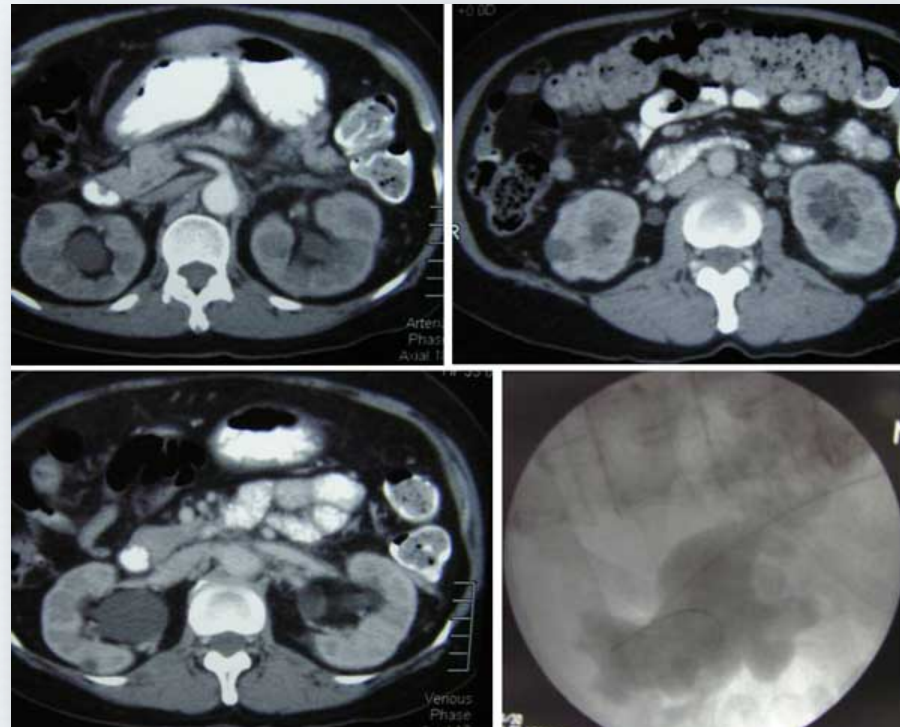
---

- Slow onset lower abdominal pain
  - Constant pressure
  - Throbbing
  - Feels a “fullness”
  - No burning, tingling shocks, etc.
- Slight vaginal discharge
- Urinary frequency

# Mrs. BL: Examination and Special Investigations

---

- Hydronephrosis with ureteric obstruction
- Secondary tumor spread



# Discussion Question

---



**WHAT TREATMENT STRATEGY  
WOULD YOU RECOMMEND?**

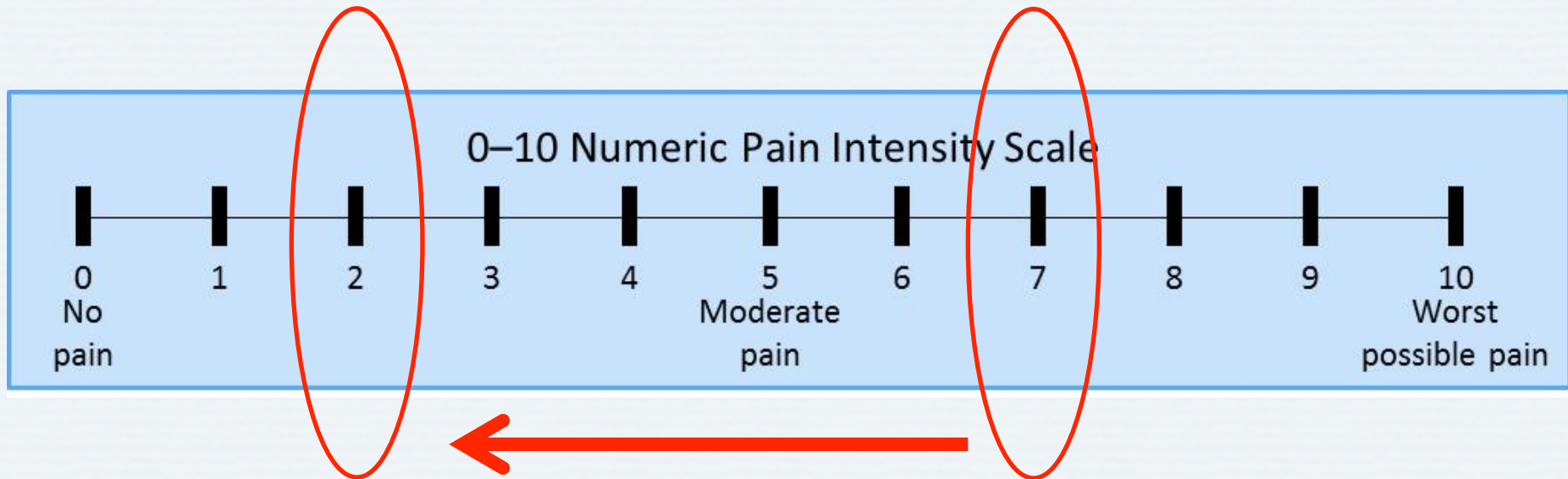
# Mrs. BL: Treatment

---

- Antibiotics for slight renal infection
  - Good response and urinary frequency stopped
- Paracetamol and tramadol combination therapy commenced
  - Pain reduced from NRS score of 7 to 2
- Referred to oncology for assessment and therapy
  - Chemotherapy started



# Mrs. BL: Numeric Rating Scale (NRS) for Pain



**The patient's pain reduced from NRS score of 7 to 2 with a combination of paracetamol and tramadol**

# Mrs. BL: Treatment (continued)

---

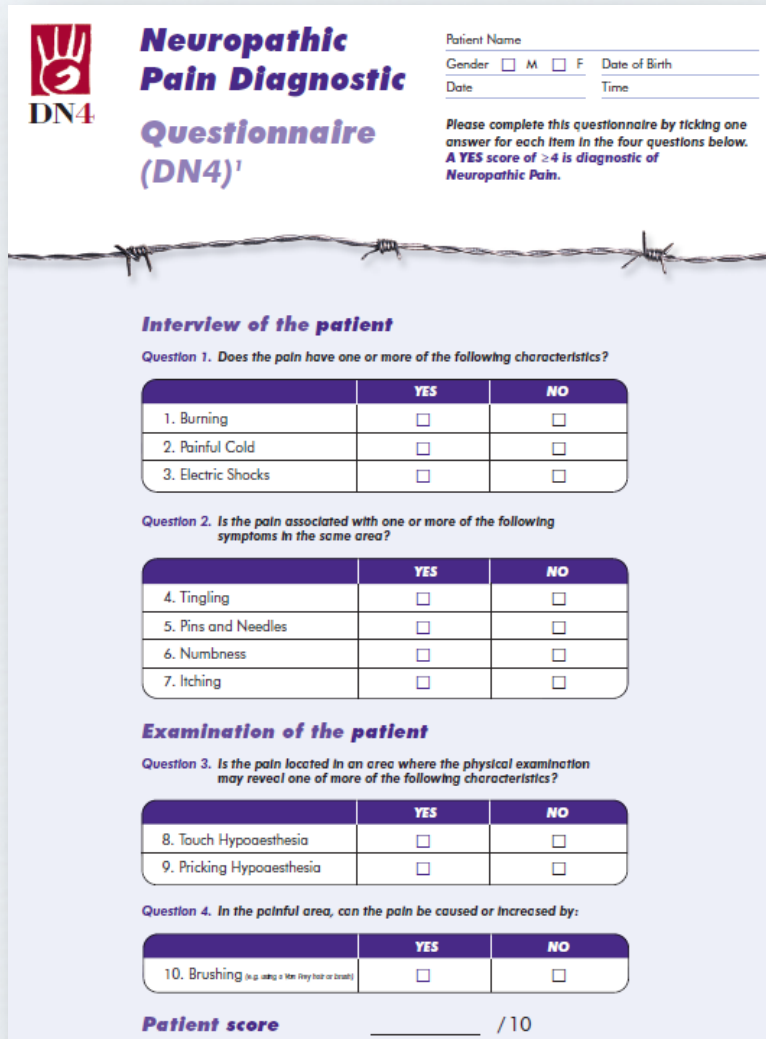
- Continued with unchanged analgesia
  - Good response with regular use
  - NRS score remained 2
- Tumor shrinkage noted
- Hydronephrosis as result of tumor obstruction resolved. No further urinary symptoms
- To be assessed every 12 weeks

# Mrs. BL: Further Symptoms

---

- Sudden onset acute leg pain 18 months later (almost 10 years after diagnosis)
- Pain characteristics
  - Shooting
  - Shocks
  - Constant
  - Pain extends to foot
- DN4 suggests neuropathic pain
- NRS score = 9

# DN4



**Neuropathic Pain Diagnostic Questionnaire (DN4)**

**DN4**

Gender  M  F Date of Birth \_\_\_\_\_  
Date \_\_\_\_\_ Time \_\_\_\_\_

*Please complete this questionnaire by ticking one answer for each item in the four questions below. A YES score of  $\geq 4$  is diagnostic of Neuropathic Pain.*

**Interview of the patient**

Question 1. Does the pain have one or more of the following characteristics?

	YES	NO
1. Burning	<input type="checkbox"/>	<input type="checkbox"/>
2. Painful Cold	<input type="checkbox"/>	<input type="checkbox"/>
3. Electric Shocks	<input type="checkbox"/>	<input type="checkbox"/>

Question 2. Is the pain associated with one or more of the following symptoms in the same area?

	YES	NO
4. Tingling	<input type="checkbox"/>	<input type="checkbox"/>
5. Pins and Needles	<input type="checkbox"/>	<input type="checkbox"/>
6. Numbness	<input type="checkbox"/>	<input type="checkbox"/>
7. Itching	<input type="checkbox"/>	<input type="checkbox"/>

**Examination of the patient**

Question 3. Is the pain located in an area where the physical examination may reveal one of more of the following characteristics?

	YES	NO
8. Touch Hypoaesthesia	<input type="checkbox"/>	<input type="checkbox"/>
9. Pricking Hypoaesthesia	<input type="checkbox"/>	<input type="checkbox"/>

Question 4. In the painful area, can the pain be caused or increased by:

	YES	NO
10. Brushing (e.g. using a New Day hair or beard)	<input type="checkbox"/>	<input type="checkbox"/>

**Patient score** \_\_\_\_\_ /10

- Completed by physician in office
- Differentiates neuropathic from nociceptive pain
- 2 pain questions (7 items)
- 2 skin sensitivity tests (3 items)
- Score  $\geq 4$  is an indicator for neuropathic pain
- Validated

# Discussion Question

---

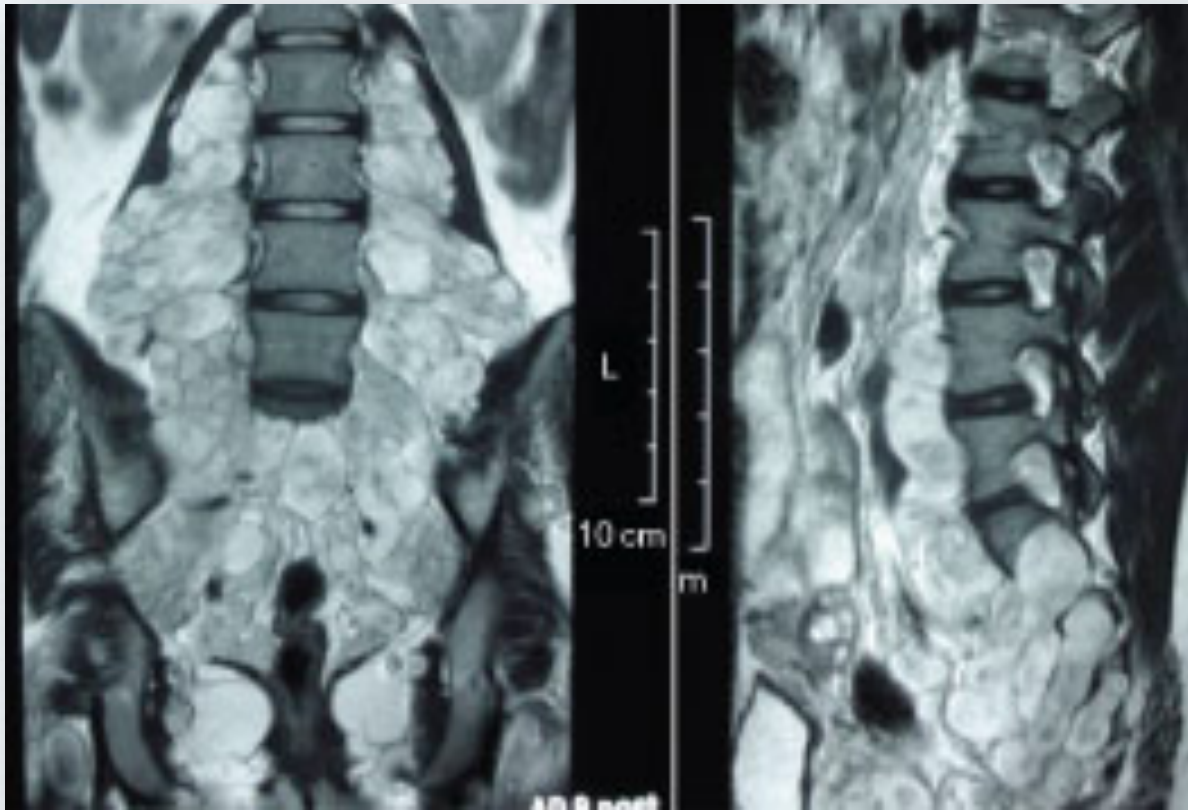
**WOULD YOU MAKE ANY CHANGES TO  
THERAPY OR CONDUCT FURTHER  
INVESTIGATIONS?**

A decorative watercolor splash is centered on the page. The upper portion is a vibrant yellow, while the lower portion transitions into a soft, light blue. The edges are irregular and feathered, giving it a hand-painted appearance.

# Mrs. BL: Further Investigation: MRI

---

- Tumor infiltration of the lumbosacral plexus



# Discussion Question

---



**WHAT TREATMENT STRATEGY  
WOULD YOU RECOMMEND?**

# Mrs. BL: Treatment

---

- Radiotherapy not suitable as widespread tumor involving nerves
- Pregabalin incrementally increased to 150 mg twice daily
  - Reduction in pain from NRS = 9 to NRS = 4
- Duloxetine added 60 mg at night
  - Further pain reduction to NRS = 2
- Patient requested continuation of both agents

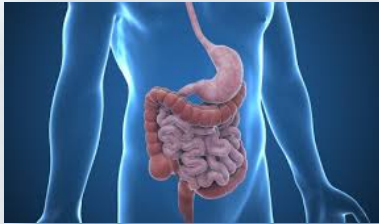

# Mrs. BL: Subsequent Progress

---

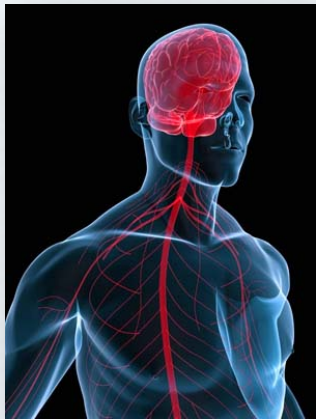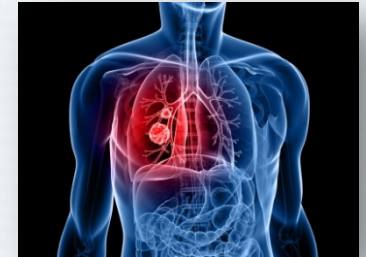- Neuropathy remained stable
  - Any attempt to reduce either drug immediately caused increase in NRS score
- Nociceptive pain increased to NRS 9 requiring ultimately high doses of morphine to control pain resulting from tumor spread 6 months later
- Morphine side effects increased with increasing doses of opioids

# Adverse Effects of Opioids



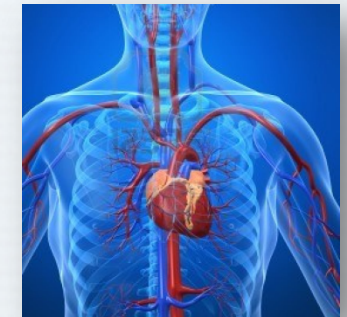- Nausea
- Vomiting
- Constipation

- Respiratory depression



- Cognitive impairment
- Sedation
- Lightheadedness
- Dizziness

- Orthostatic hypotension
- Fainting



## Other

- Itching
- Miosis
- Sweating
- Urinary retention

CNS = central nervous system

Moreland LW, St Clair EW. *Rheum Dis Clin North Am* 1999;25(1):153-91; Yaksh TL, Wallace MS. In: Brunton L et al (eds). *Goodman and Gilman's The Pharmacological Basis of Therapeutics*. 12th ed. (online version). McGraw-Hill; New York, NY: 2010.

# Discussion Question

---



**WHAT TREATMENT STRATEGY  
WOULD YOU RECOMMEND?**

# Mrs. BL: Further Management

---

- Chemotherapy stopped because tumor growth continued despite therapy
- Renal function monitored and remained good
  - GFR
  - CrCl
- Neuropathic medical therapy (pregabalin + duloxetine) controlled plexus infiltration neuropathy
- Nociceptive pain required further intervention
  - Use of intrathecal pump for morphine

# Opioids for Cancer Pain

**Opioid-based pharmacotherapy is the mainstay of symptomatic treatment of cancer pain**

- Are safe for the management of cancer pain
- Provide a good balance between efficacy (pain relief) and side effects
- Misuse, addiction, and diversion are not relevant concerns in patients with cancer pain

# Use of Opioids for Cancer Pain

- Skilled use of opioids is crucial to relief of cancer pain
- Mild to moderate/uncontrolled pain with acetaminophen or NSAID: add a step 2 or 3\* opioid given orally
- Immediate-release and slow-release oral formulations of morphine, oxycodone, and hydromorphone can be used for dose titration
- Transdermal fentanyl and buprenorphine are alternatives to oral opioids
- Breakthrough pain should be treated with additional doses of immediate-release oral opioids

# Opioids Used for Cancer Pain

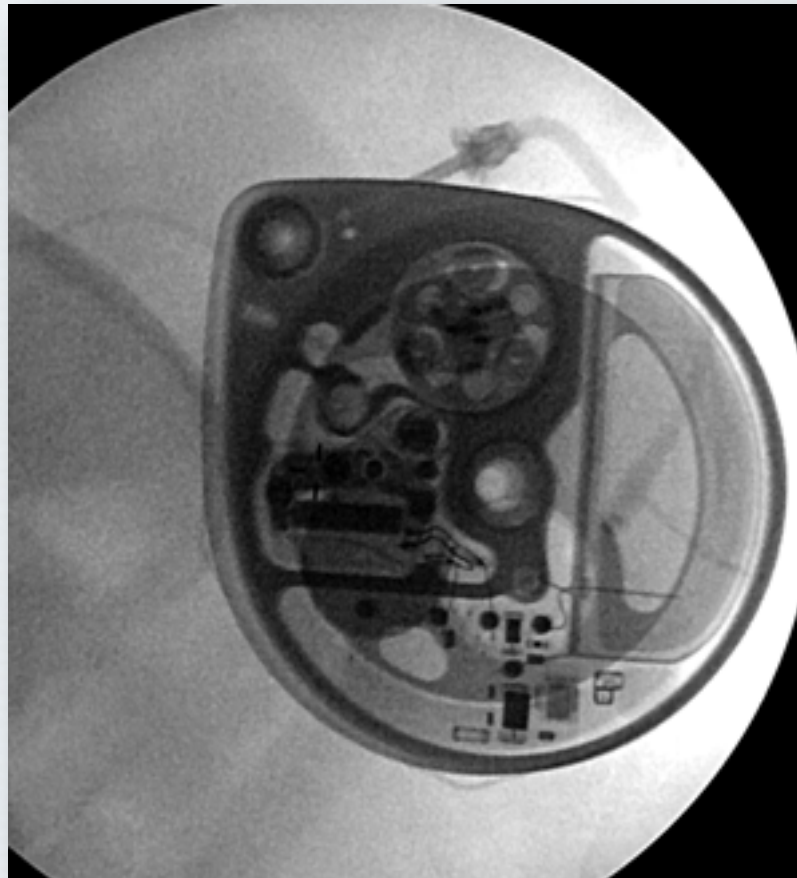
- Tramadol
- Codeine
- Hydromorphone
- Levorphanol
- Methadone
- Tapentadol

- Morphine
- Oxycodone
- Hydrocodone
- Oxymorphone
- Fentanyl

# Mrs. BL: Intrathecal Pump System

---

- Morphine 1500  $\mu\text{g}$  per day





# Conclusion

---

- Cancer pain can have both nociceptive and neuropathic components.
- Neuropathic pain was well managed with pregabalin and duloxetine.
  - Two mechanisms for pain control were necessary.
- Nociceptive pain was well managed using opioids (morphine).
- The patient sadly demised 18 months later as a result of renal failure following bilateral ureteric obstruction. She was virtually pain free and was very comfortable at the time of death.

---

Case: Mr. HS



# Mr. HS: Profile

---

- A 54-year-old male, government officer
- Complaint of pain in the right upper anterior chest wall and upper back for 2 months
- His pain has progressively increased
  - Pain does not respond to oral paracetamol
- He had history of smoking 1 pack/day for >20 years

# Discussion Questions

---

**WHAT FURTHER HISTORY WOULD YOU LIKE TO KNOW?**

**WHAT TESTS OR EXAMINATIONS WOULD YOU CONDUCT?**

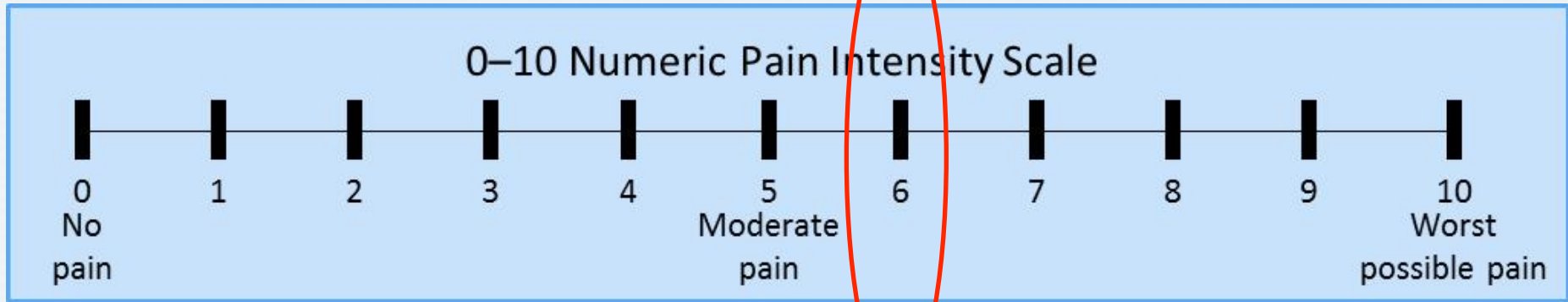
# Mr. HS: Pain History

---

- **Onset:** 2 months ago
- **Area:** right upper anterior chest wall and upper back
- **Characteristics:** burning, tingling, aching inside
- **Timing:** continuous pain even at rest
- **Intensity:** NRS for pain = 6
- **Effects of pain:** boring, suffering, sleep disturbance
- **Aggravating factors:** movement, pressing or touching at the pain area
- **Relieving factors:** none

# Mr. HS: Numeric Rating Scale (NRS) for Pain

---



**The patient's pain score is 6**

# Mr. HS: Physical Examination

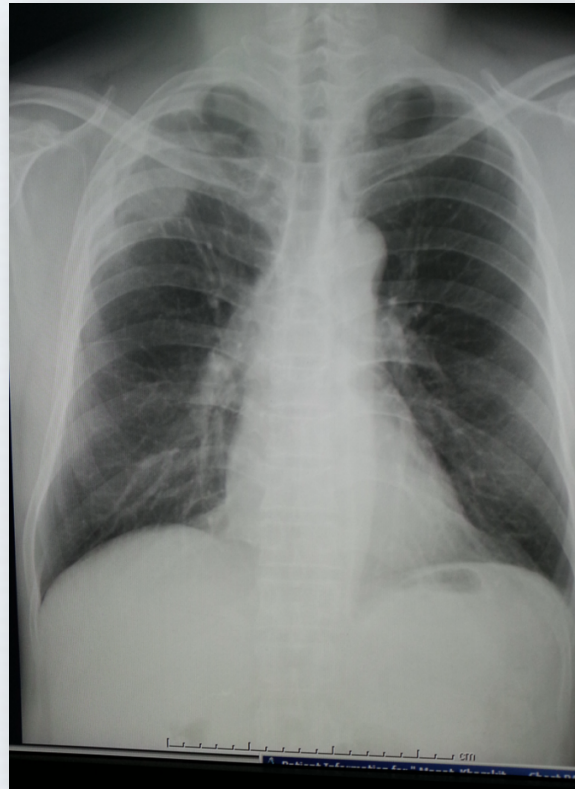
---

- Conscious, co-operative
- Weight = 67.9 kg; height = 168 cm; BMI = 24.1 kg/m<sup>2</sup> (normal)
- Vital signs were in normal limits
- HEENT: normal; no superficial lymphadenopathy
- Tenderness at the right anterior chest wall
- Lungs: clear
- Abdomen: soft
- Extremities: no edema

# Mr. HS: Initial Investigations

---

- CBC and blood chemistry: normal
- Chest X-ray revealed a right apical lung mass





# What would your differential diagnosis for Mr. HS be?


---

- Right apical lung mass may be from
  - Lung cancer
  - Infection (*e.g.*, tuberculosis, mycoses)
  - Lymphoma

**The patient should be referred for specific investigations and treatments.**

# Mr. HS: Specific Investigations

---

- CT scan of the chest: right upper lung mass 1.8x2x3.5 cm. irregular border with invasion of intercostal muscles. Multiple subpleural nodules
  - Transthoracic needle biopsy: adenocarcinoma
- 

# Mr. HS: Diagnosis

---

- Non-squamous cell lung carcinoma (NSCLC), stage T8N1M0

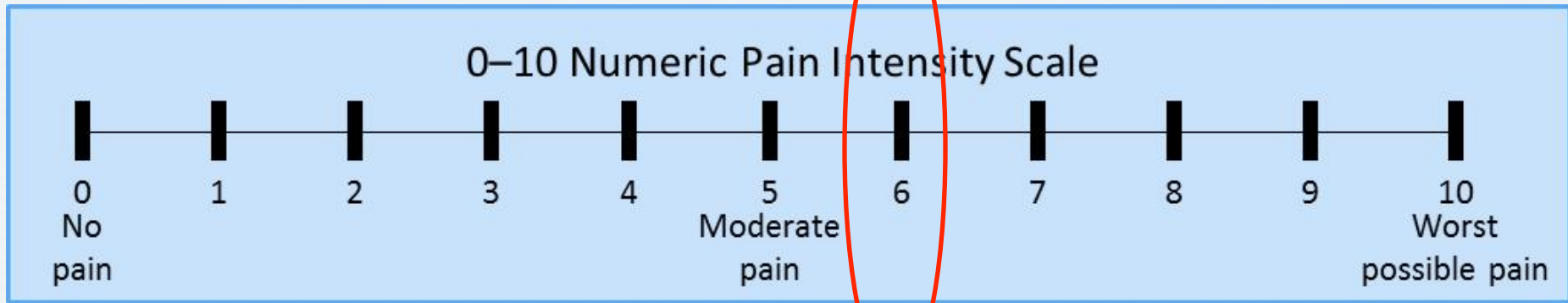
# Discussion Questions

---

- **HOW COULD YOU ASSESS HIS PAIN?**
- **WHAT TYPES OF PAIN HAS HE HAD?**
- **WHAT IS THE SEVERITY OF HIS PAIN?**
- **WHAT IS THE IMPACT OF HIS PAIN?**

# Mr. HS: Numeric Rating Scale (NRS) for Pain

---



**The patient's pain score is 6**

# Mr. HS: Short Form of Brief Pain Inventory

FORM 3.2 **Brief Pain Inventory**

Date: \_\_\_/\_\_\_/\_\_\_ Time: \_\_\_\_\_

Name: Mr. HL  
Last First Middle Initial

1) Throughout our lives, most of us have had pain from time to time (such as minor headaches, sprains, and toothaches). Have you had pain other than these everyday kinds of pain today?  
 1.  Yes 2. No

2) On the diagram shade in the areas where you feel pain. Put an X on the area that hurts the most.

3) Please rate your pain by circling the one number that best describes your pain at its **worst** in the past 24 hours.  
 0 1 2 3 4 5 6 7  8 9 10  
 No pain pain as bad as you can imagine

4) Please rate your pain by circling the one number that best describes your pain at its **least** in the past 24 hours.  
 0 1 2 3 4  5 6 7 8 9 10  
 No pain pain as bad as you can imagine

5) Please rate your pain by circling the one number that best describes your pain on the **average**  
 0 1 2 3 4 5  6 7 8 9 10  
 No pain pain as bad as you can imagine

6) Please rate your pain by circling the one number that tells how much pain you have **right now**.  
 0 1 2 3 4 5  6 7 8 9 10  
 No pain pain as bad as you can imagine

7) What treatments or medications are you receiving for your pain?  
paracetamol

8) In the Past 24 hours, how much **relief** have pain treatments or medications provided? Please circle the one percentage that most shows how much relief you have received  
 0% 10  20 30 40 50 60 70 80 90 100%  
 No Complete relief

9) Circle the one number that describes how, during the past 24 hours, pain has **interfered** with your:

A. General activity  
 0 1 2 3 4 5 6 7  8 9 10  
 Does not interfere Completely interferes

B. Mood  
 0 1 2 3 4 5 6 7 8  9 10  
 Does not interfere Completely interferes

C. Walking ability  
 0 1 2 3 4  5 6 7 8 9 10  
 Does not interfere Completely interferes

D. Normal work (includes both work outside the home and housework)  
 0 1 2 3 4 5 6 7  8 9 10  
 Does not interfere Completely interferes

E. Relations with other people  
 0 1 2 3 4 5 6 7  8 9 10  
 Does not interfere Completely interferes

F. Sleep  
 0 1 2 3 4 5 6 7  8 9 10  
 Does not interfere Completely interferes

G. Enjoyment of life  
 0 1 2 3 4 5 6 7  8 9 10  
 Does not interfere Completely interferes

# Mr. HS: Results of Initial Pain Assessment

---

- Mixed pain [neuropathic pain (major) and nociceptive pain( minor)]
- Moderately severe pain (NRS for pain = 6)
- Sleep disturbance, anxious (using short form of BPI)
  - BPI score of sleep disturbance and anxiety of 8 and 9, respectively

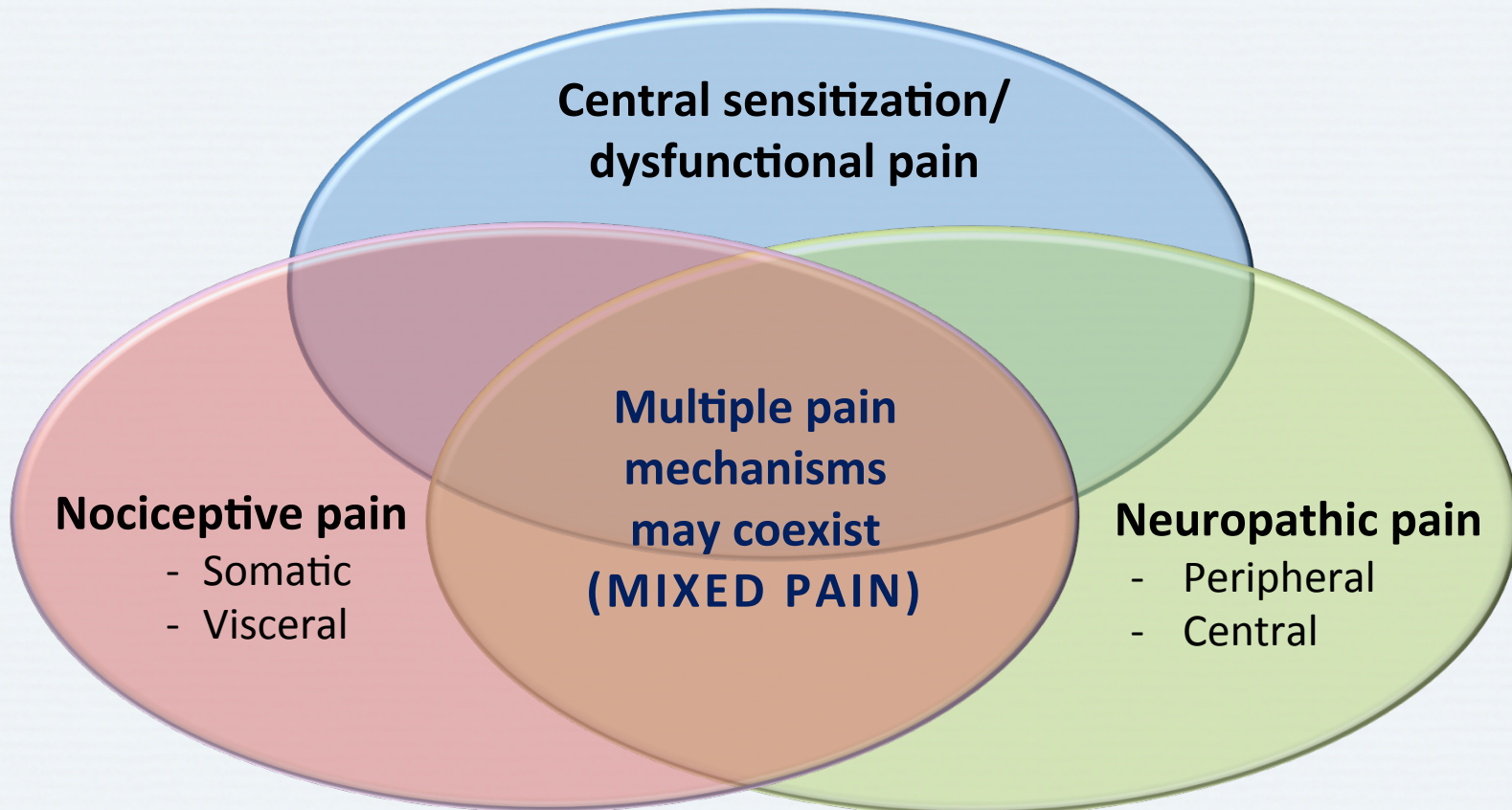
# Discussion Questions

---

- **WHAT WAS THE UNDERLYING PATHOPHYSIOLOGY OF HIS PAIN?**
- **WHAT APPROACH WOULD YOU USE TO MANAGE THIS PATIENT'S PAIN?**

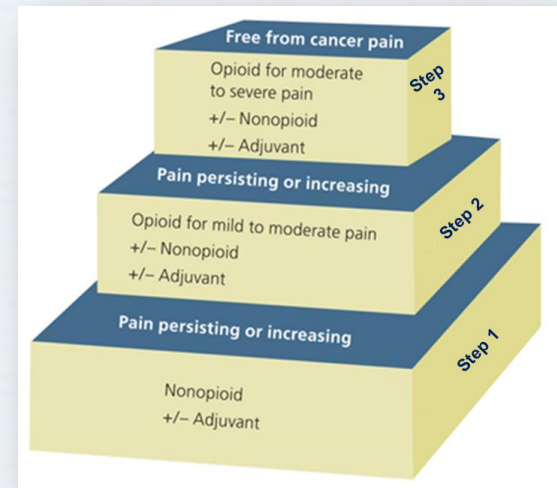


# Pathophysiological Classification of Pain



# Mr. HS: Initial Pain Treatment

- Patient has mixed pain [neuropathic pain (major) and nociceptive pain( minor)]
- Medication based on WHO analgesic ladder
  - Gabapentin (300 mg) 1 cap bid
  - Tramadol (50 mg) 1 cap prn every 6 hr



# Mr. HS: Specific Treatment

---

- Induction chemotherapy (CMT) for 3 cycles using carboplatin
- Follow up one month after induction CMT (6 months after initial diagnosis)
- Chest X-ray: slight increase in size of mass in right upper lung
- Bone scan: increase uptake of right 1<sup>st</sup>, 3<sup>rd</sup>-5<sup>th</sup> ribs, transverse process of T3 and left side of L5 vertebra
- Impression: failure of induction CMT
- Plan: Consider second-line CMT using docetaxel 6 cycles (in 3 months)

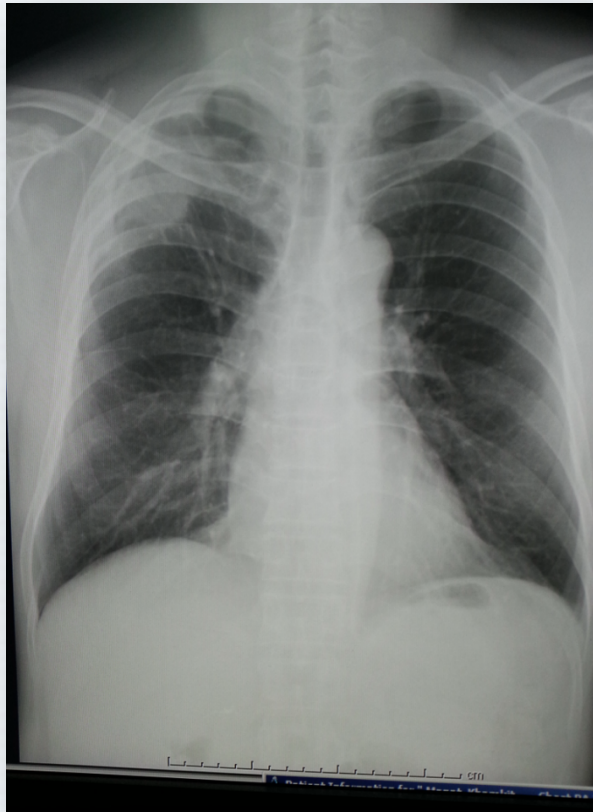
# Mr. HS: Continued Treatment and Pain

---

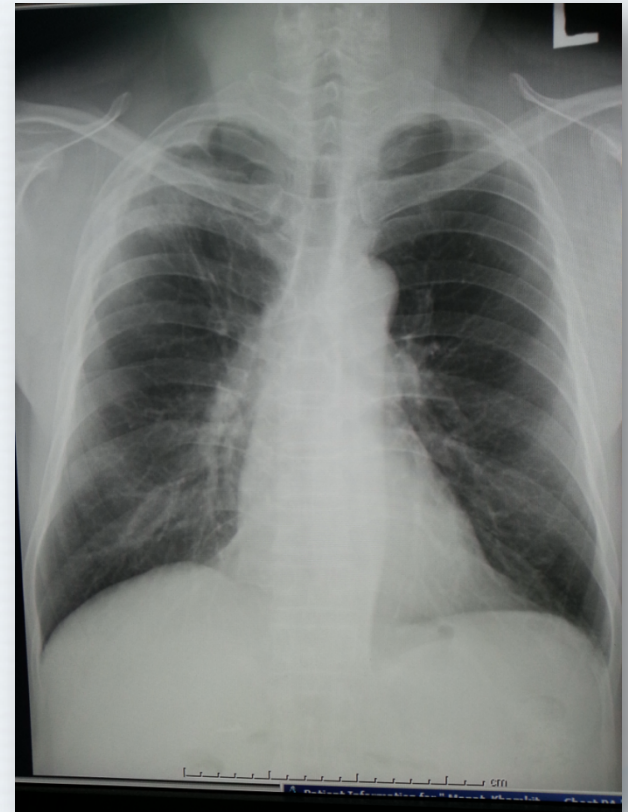
- Because of the failure of induction CMT, his burning pain at the right anterior chest wall was increasing (pain score = 8)
  - Dosages of gabapentin and tramadol were increasing accordingly
- After first cycle of docetaxel (7 months), the pain and the size of the lung mass were decreased
  - He could reduce the dosage of the pain medications
- Plan of cancer treatment: concurrent chemoradiation 70Gy/35F

# Mr. HS: Follow-up Chest X-rays

---



Before treatment



At 7 months after 1<sup>st</sup> cycle  
of doxorubicin

# Mr. HS: New Pain

---

- Two months after 1st docetaxel (9 months), pain at the chest wall was minimal but the patient started to have pain in the left hip, radiating to left leg
- Pain medications: gabapentin, COX-2 inhibitor, amitriptyline, tramadol prn


# Discussion Questions

---

- **HOW COULD YOU ASSESS HIS NEW PAIN?**
- **WHAT TYPES OF NEW PAIN HAS HE HAD?**
- **WHAT IS THE SEVERITY OF HIS NEW PAIN?**
- **WHAT IS THE IMPACT OF HIS NEW PAIN?**

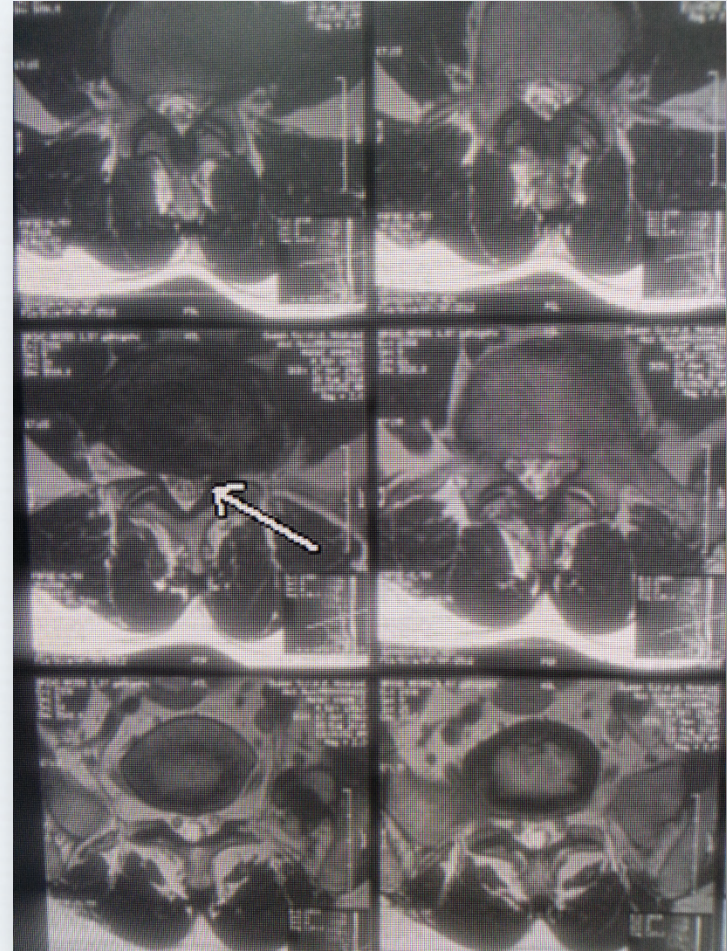
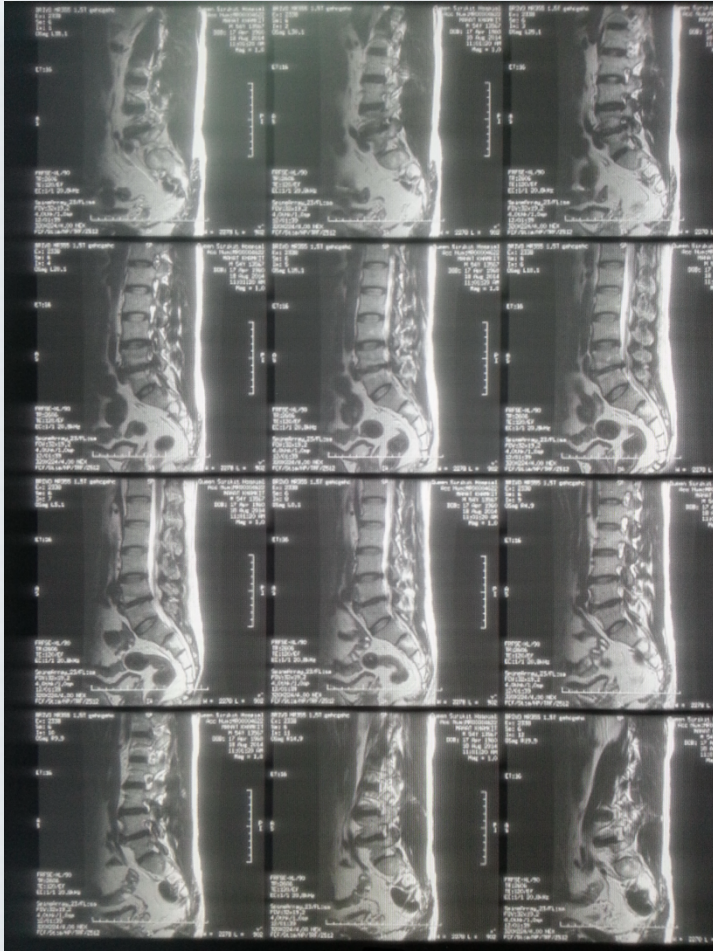# Mr. HS: Further Investigations

---

- Chest X-ray and CT-chest: No significant changes
  - X-ray LS spine: stable sclerotic lesion L5
  - MRI LS spine (9 months): central disc herniation at L4/5 caused narrow bilateral neural foramen.
  - No evidence of LS spine metastasis
- 



# Mr. HS: MRI of LS Spine for Low Back Pain (9 Months)



# Discussion Question


---



**WHAT ARE YOUR DIAGNOSES?**

# Mr. HS: Diagnoses

---

1. Non-squamous cell lung carcinoma (NSCLC), stage T8N1M0 with metastasis to right ribs 1,3,5 and suspected metastasis to spine (from bone scan)
  2. Lumbar disc herniation L4/5
  3. Left radicular pain (neuropathic pain)
- 

# Mr. HS: History

---

- **Four months after 1<sup>st</sup> docetaxel** (11 months), pain at the anterior of both thighs and numbness in both feet were reported
  - Mild pain at the anterior chest wall
  - Body weight = 72 kg
- **Five months after 1<sup>st</sup> docetaxel** (12 months), he complains of increasing pain and numbness in the legs
  - NRS for pain in his left leg = 9
  - He cannot sit long (body weight = 66.6 kg)
  - Bowel and bladder control are normal
  - Bone scan: positive at right ribs 5-8

# Mr. HS: History

---

- Seven months after 1<sup>st</sup> docetaxel (14 months), he had progressive weakness and could not control bladder function
- A neurological examination was done.

# Mr. HS: Neurological Examination

---

- Glasgow Coma Scale: E4V5M6,
- Normal oculomotor function, no facial palsy
- Motor power
  - Upper extremities – grade V/V
  - hip, knee – grade IV/V
  - ankle – grade 0/0
- Sensory: intact
- Reflexes
  - Upper extremities: 2+
  - Lower extremities: 0

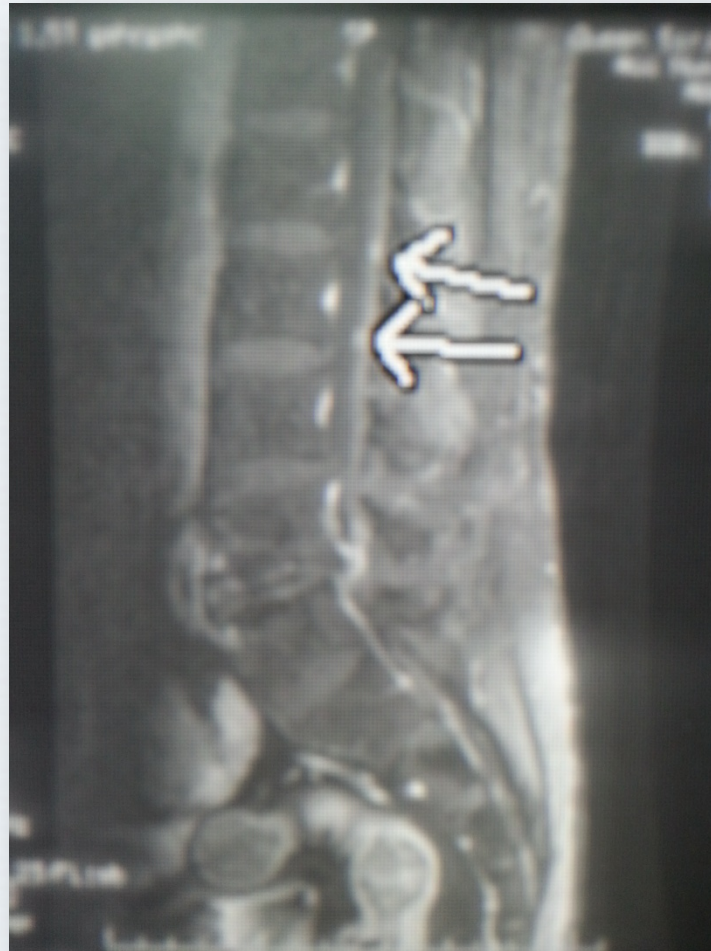# Mr. HS: Further Investigations

---

- MRI of LS spine (14 months):
  - No definite bony destruction or enhancement
  - Drop metastasis at the conus medularis, cauda equina nerve root, left L2 and right L3 nerve roots
- Chest X-ray: unchanged

# Mr. HS: MRI of LS spine (14 months) Leptomeningeal (Drop) Metastasis

---





# Mr. HS: Laboratory Findings

---

## CSF study:

- Appearance - clear
- WBC 70/HF with monocyte 99% (normal: WBC 0-5/HF with monocyte 30-50%)
- RBC 100/HF (normal: 0/HF)
- Glucose 49 mg/dL (normal: 40-70 mg/dL)
- Total protein 231.5 mg/dL (normal: 15-50 mg/dL)

# Discussion Question

---



**WHAT ARE YOUR DIAGNOSES  
AND TREATMENT RECOMMENDATION?**

# Mr. HS: Diagnosis

---

1. Non-squamous cell lung carcinoma (NSCLC), stage T8N1M0 with multiple rib metastasis
2. Lumbar disc herniation L4/5
3. Leptomeningeal metastasis with cauda equina syndrome

**Urgent management (for red flag) was considered as palliative care.**

# Mr. HS: Treatment Plan – Palliative Care

---

- He was admitted for palliative radiation T12-L5 30Gy/10F
- Analgesics and adjunctive medications:
  - Gabapentin
  - Tramadol
  - Morphine IV as rescue medication
  - Dexamethasone
- Physiotherapy

**The patient responded well to palliative radiation and continued with palliative care.**

# Mr. HS: Case Conclusion

---

- Cancer pain can have both nociceptive and neuropathic components.
- The underlying causes of nociceptive and neuropathic pain should be established and specifically treated if possible.
- Medications for management of pain as symptom control were based on the pathophysiology (mechanisms) of pain.
- Intractable neuropathic pain was well managed pharmacologically by anticonvulsants, antidepressants and if necessary, opioids.
- The patient with metastatic cancer might respond well to palliative radiation. Improvement of his quality of life was the main goal.
- Psychosocial intervention can always be integrated in the treatment program of cancer pain.

---

Case: Mr. HL




# Mr. HL: Profile

---

- 56-year self-employed old male
- History of cancer of the rectum, unresectable
- Status post-palliative colostomy and chemotherapy
  - Admitted because of partial gut obstruction with abdominal and perianal pain

# Mr. HL's Abdominal Pain

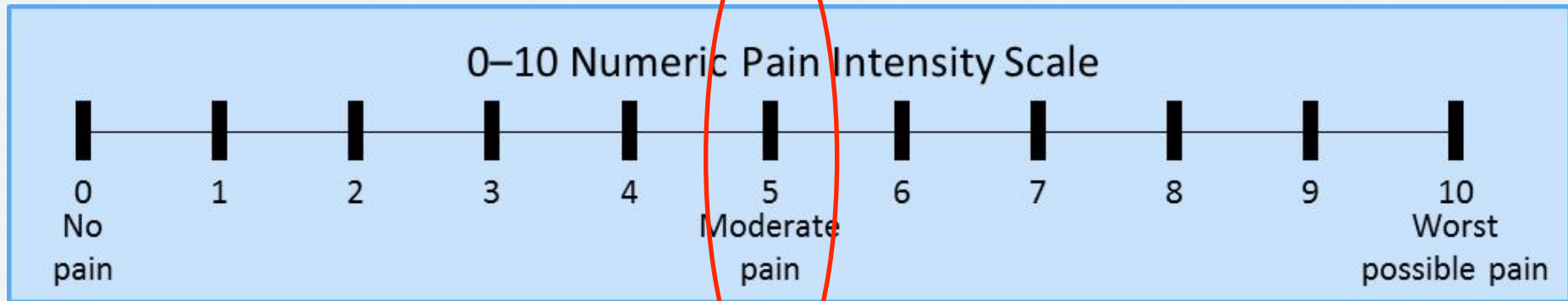
---

- Abdominal pain was continuous, dull, and aching
  - Sometimes spasmodic
  - Mostly in the lower abdomen
  - Pain score = 5 using the numeric rating scale
- 



# Mr. HL: Numeric Rating Scale (NRS) for Pain


---



**The patient's abdominal pain score is 5**

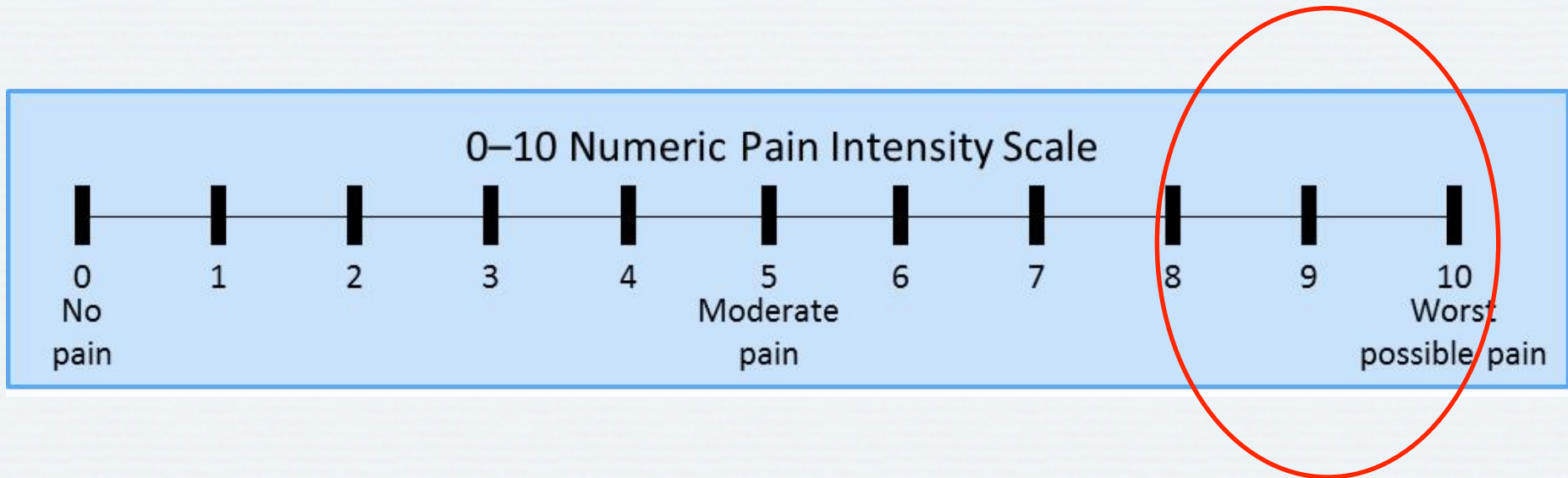
# Mr. HL's Perianal Pain

---

- His perineal pain was the most serious one with the feeling like to defecate and tenesmus almost all day long
  - Pain score = 8-10 using numeric rating scale
- 

# Mr. HL: Numeric Rating Scale (NRS) for Pain

---



**The patient's perianal pain score is 8-10**

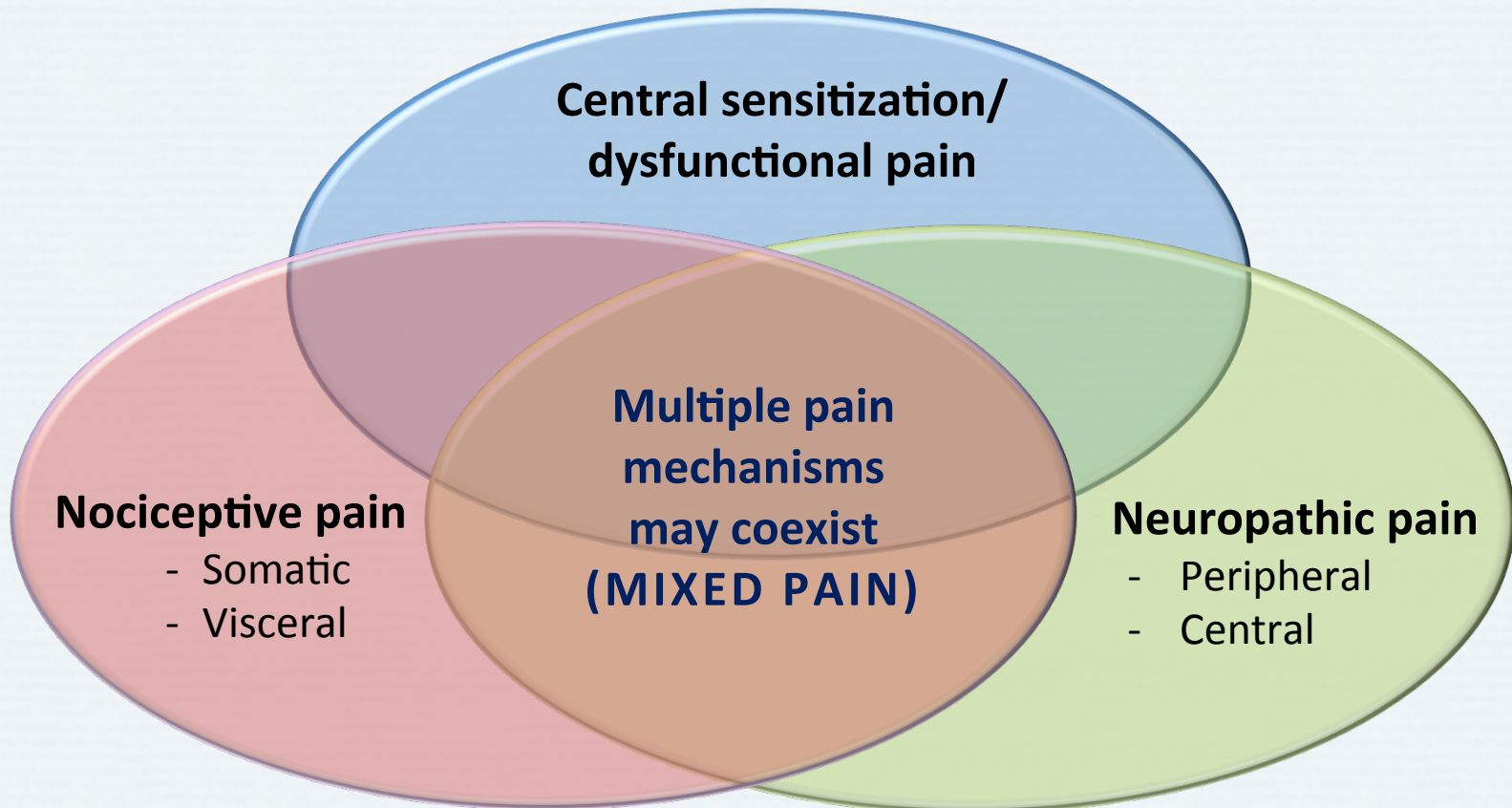
# Discussion Question

---



**WHAT WAS THE UNDERLYING  
PATHOPHYSIOLOGY OF HIS PAIN?**

# Pathophysiological Classification of Pain



# Mr. HL: Underlying Pathophysiology

---

- This patient is suffering from nociceptive visceral pain both in the abdomen and at the perineum.
- Visceral pain at the perineum conveys via sacral sympathetic chains (S2-S4).<sup>1,2</sup>
- He can also experience coexisting nociceptive somatic and neuropathic pain.
- Neuropathic pain at the perineum may be caused by tumor invasion to the adjacent nervous system.
- Prolonged and intense visceral pain can cause central sensitization and worsen the pain.

# Discussion Question

---



**WHAT TREATMENT STRATEGY  
WOULD YOU RECOMMEND?**

# Mr. HL: Treatment

---

- Multidisciplinary pain management should be considered using both pharmacological and non-pharmacological approaches
- Medications
  - MST 90 mg every 12 h
  - Pregabalin was titrated up to 150 mg in the morning, 150 mg in the afternoon and 300 mg at bed time
  - Amitriptyline 75 mg at night
  - Morphine IV as rescue medication



# Mr. HL: Results

---

- His abdominal pain was improved but the perineal pain did not change much.

**Consider interventional pain treatment for intractable perineal pain from cancer of the rectum.**

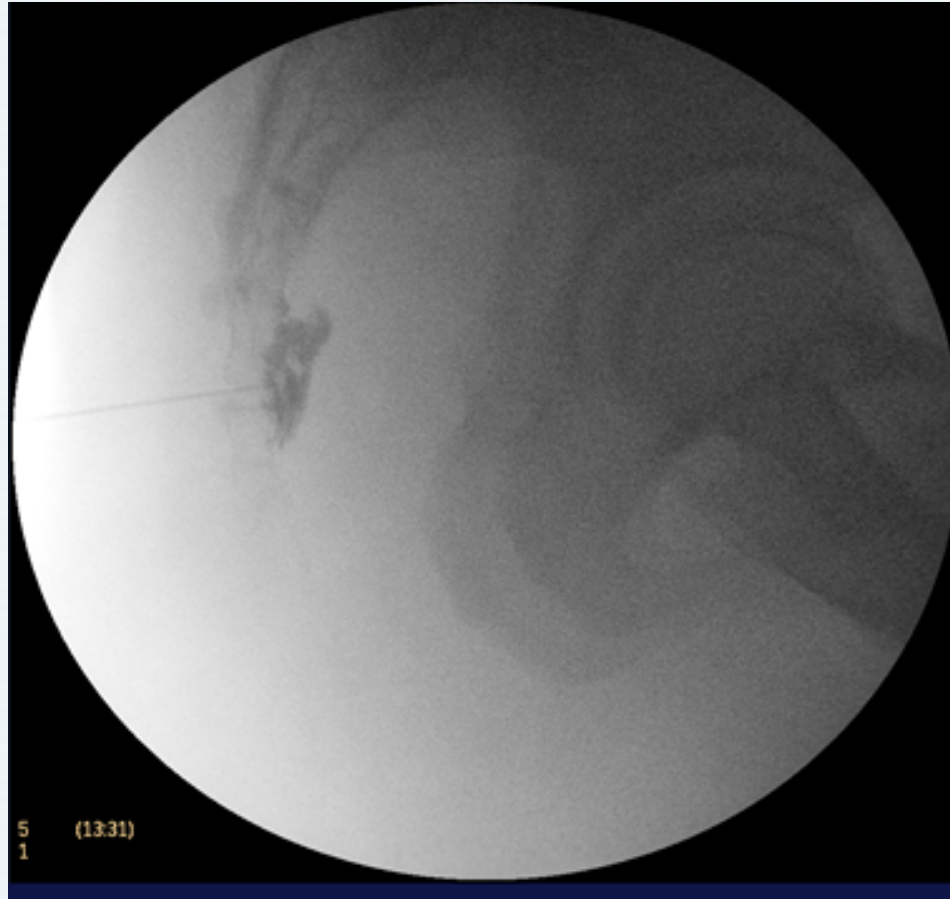# Discussion Question

---

**WHAT INTERVENTION PAIN  
TREATMENT WOULD YOU  
RECOMMEND FOR PERINEAL PAIN?**

# Mr. HL: Ganglion Impar Neurolysis with Absolute Alcohol 4 mL

---



# Mr. HL: Results

---

- The perineal pain was totally relieved after Ganglion Impar neurolysis with absolute alcohol 4 mL
- Dosage of pain medications was dramatically reduced with effective pain control
  - MST 30 mg every 12 h
  - Pregabalin 75 mg in the morning, 150 mg at night

**His cancer-related pain was well controlled till the end of his life in 1 month.**

# Mr. HL: Case Conclusion

---

- Visceral cancer pain may be difficult to treat.
- Nociceptive visceral pain might be well managed using opioids (*e.g.*, morphine).
- Prolonged and intense visceral pain can cause central sensitization or tumor invasion of adjacent nerve plexus causes neuropathic pain.
  - Therefore, medications for neuropathic pain may have roles in this condition.
- Interventional pain treatment for intractable visceral pain should be considered when appropriate.
- Psychosocial intervention can always be integrated in the treatment program of cancer pain.

---

Case: Mr. NP



# Mr. NP: Profile

---

- 39-year-old male, office employee
- Lung cancer for >1 year
- Thoracotomy of parts of the right lung one year ago
- Cancer progression despite different chemotherapies
  - Patient elected to stop any further chemotherapy
- Patient was admitted to palliative care unit due to strong pain in right chest
  - Patient was unable to walk or prepare his meals

# Discussion Question

---



**WHAT TREATMENT STRATEGY  
WOULD YOU RECOMMEND?**



# Mr. NP: Treatment

---

- Patient was treated with 320 mg oxycodone/day
- Co-medication = diclofenac 75 mg bid + metamizole 4 g/day
- Morphine (10 mg) up to 13 times daily for breakthrough pain

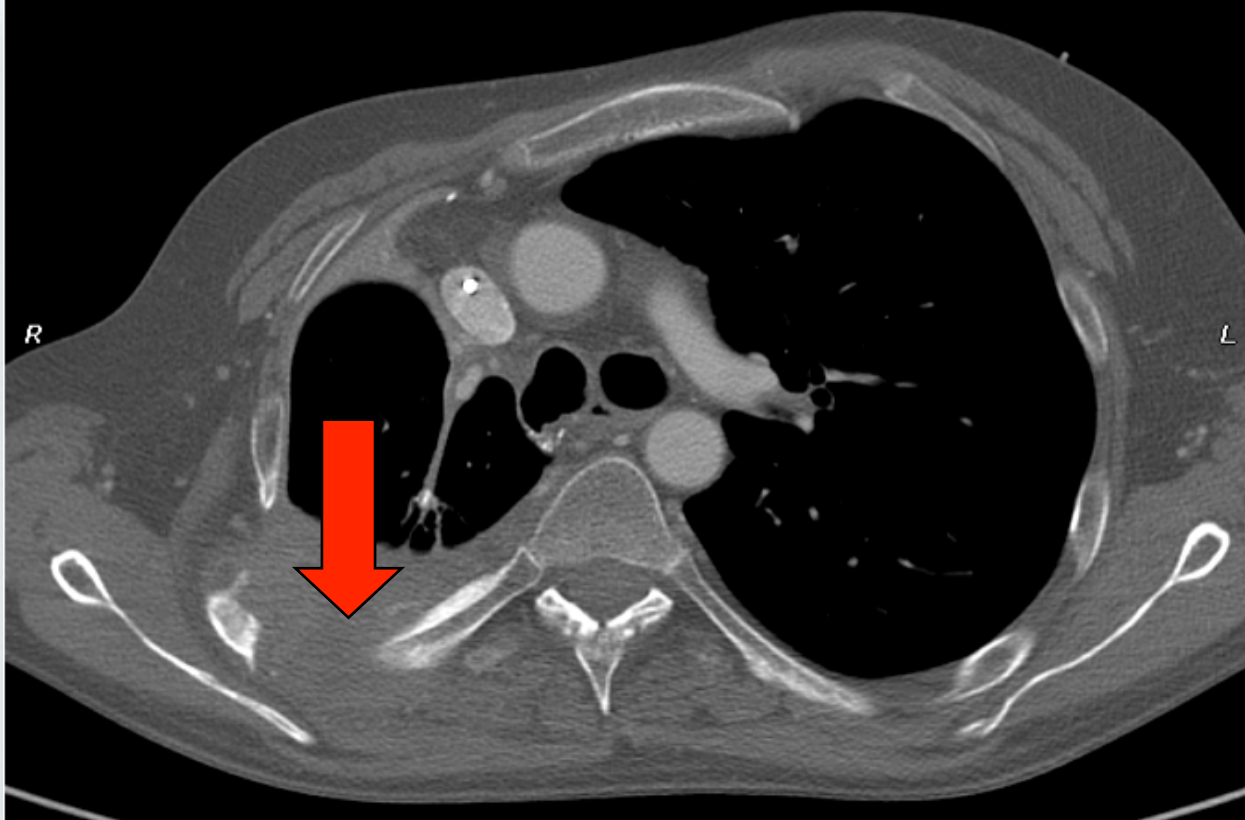
# Discussion Questions

---

**WHAT TESTS OR EXAMINATIONS WOULD YOU CONDUCT?**

# Mr. NP: CT Imaging – Lung Cancer

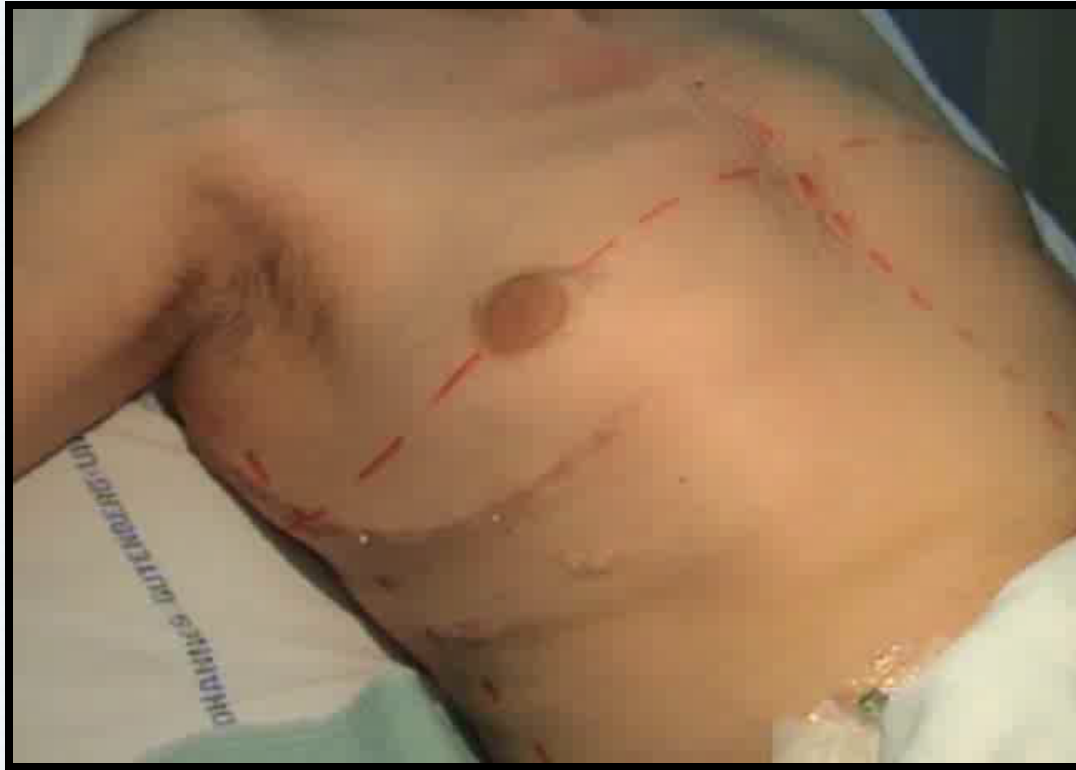---



- A year later primary surgery cancer returned (red arrow)
- Now infiltrating bony structures and intercostal nerves

# Mr. NP: Clinical Examination – Q-tip and Pinprick


---



- In the area of cancer progression, including infiltration of intercostal nerves, the patient felt numbness and pain
- Adjacent areas showed mechanical allodynia and hyperalgesia

# Mr. NP: Summary of Clinical Findings

---

- Mr. NP showed numbness over the most painful spot of his right chest in the area of cancer growth
  - Distribution of the sensory deficit and CT imaging was consistent with neuroanatomically plausible damage of intercostal nerves
  - Adjacent areas demonstrated mechanical allodynia and hyperalgesia
- 

# Discussion Questions

---

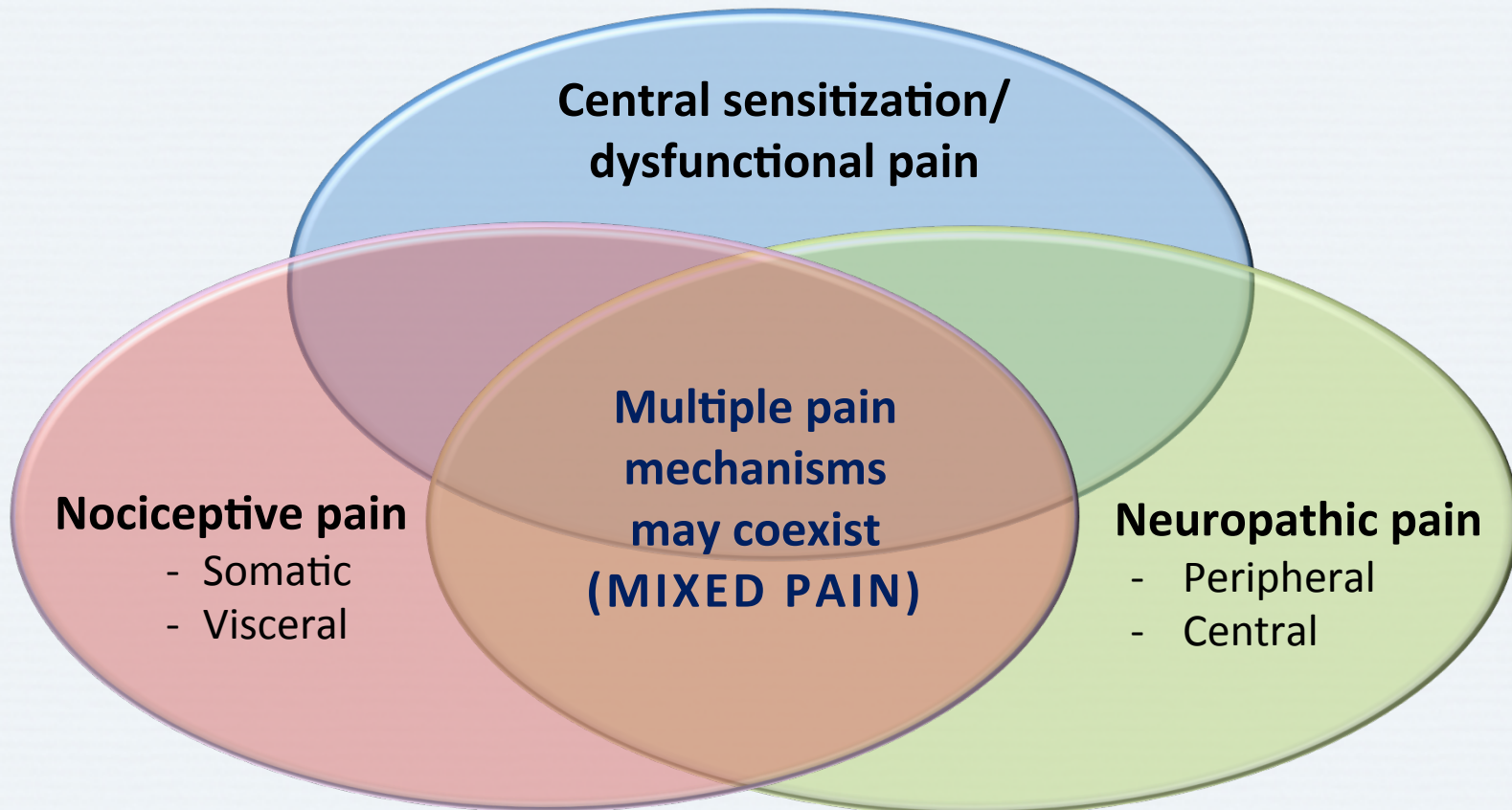
**BASED ON THE CASE PRESENTATION,  
WHAT WOULD YOU CONSIDER IN YOUR  
DIFFERENTIAL DIAGNOSIS?**

# Mr. NP: Diagnosis

---

- Clinical findings point to a definite **neuropathic pain** directly arising after cancer-related damage of intercostal sensory nerves

# Pathophysiological Classification of Pain





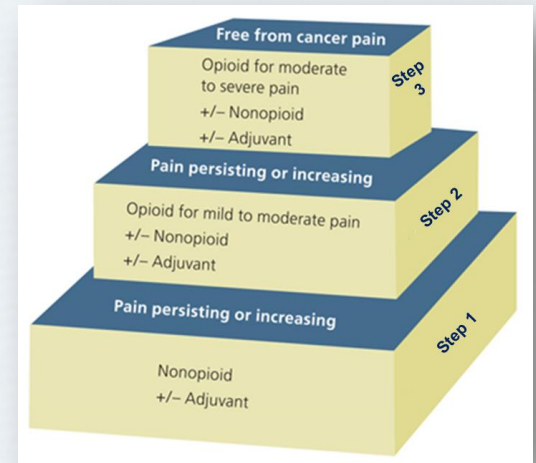
# Discussion Questions

---

**WHAT OTHER TESTS OR EXAMINATIONS  
WOULD YOU CONDUCT?**

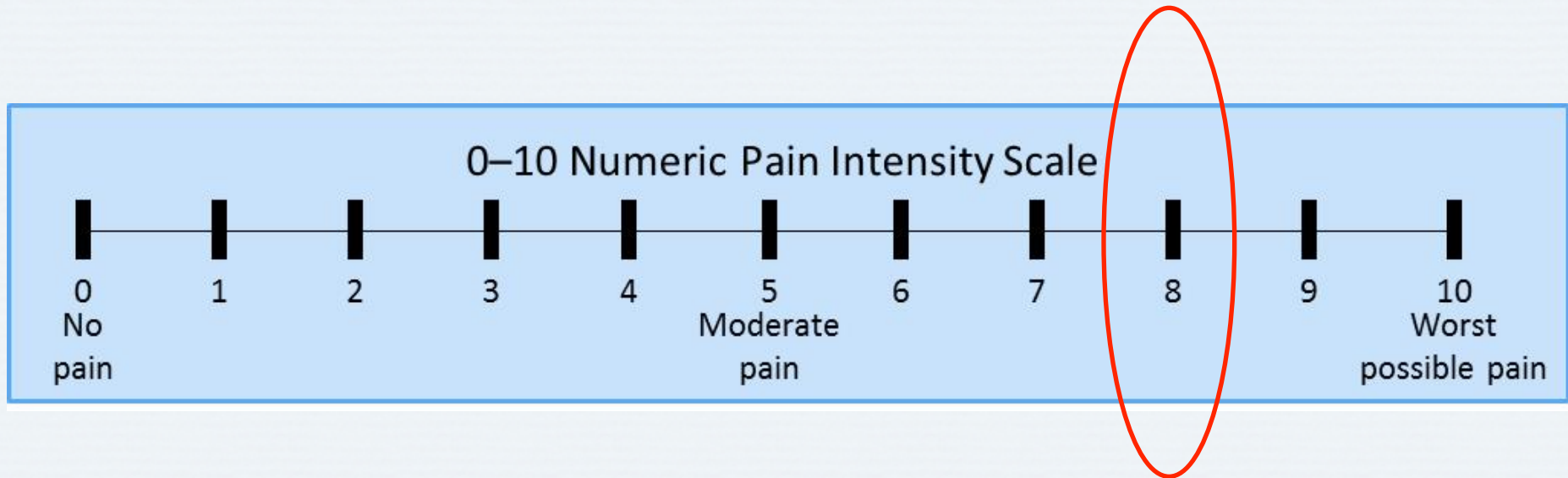
# Mr. NP: Further Examination

- Mr. NP reported high pain intensities (VAS score = 8) under treatment following the WHO pain ladder using NSAIDs and strong opioids
- He was still unable to walk, wash himself without help, or enjoy his meals while sitting at a table
- His sleep was often disturbed
  - High pain intensity even during rest was accompanied by anxiety



# Mr. NP: Visual Analog Scale (VAS) for Pain

---



**The patient's score is 8**

# Discussion Question

---



**WHAT TREATMENT STRATEGY  
WOULD YOU RECOMMEND?**

# Mr. NP: Pharmacological Management

---

- The rather small dose of morphine rescue medication was adjusted, corresponding to about 1/6<sup>th</sup> of the mean daily basal opioid use
- Opioid treatment was rotate from oxycodone to continuous intravenous hydromorphone therapy
- Pregabalin was added for the neuropathic pain component
  - Titrated up to 150 mg bid

# Mr. NP: Quality of Life

---

- With pharmacological treatment, Mr. NP showed reduced sensory signs and less mechanical allodynia and hyperalgesia
- He was able to leave his bed with increased daily activities
- His sleep improved
- His level of anxiety decreased
- As the level of pain increased with increased activity, palliative radiation therapy was started
  - Supported stable pharmacological pain control over the next 6 months

---



**WOULD YOU MAKE ANY CHANGES TO  
THERAPY OR CONDUCT FURTHER  
INVESTIGATIONS?**



# Mr. NP: Case Conclusion

---

- Mr. NP was happy with the level of pain control over the next 6 months
- He spent two weeks on holiday with his wife
- A stable opioid dose was administered continuously via IV syringe drive
- Pregabalin was increased from 300 mg/day to 450 mg/day two months later to control increasing allodynia




---

# Case: Mrs. PC



# Mrs. PC: Profile

---

- 73-year-old woman, retired
  - Was diagnosed in 2012 with motor neuron disease
  - Has walked with walking aids ever since
  - In February 2014 she complains of abdominal pain
  - She has not experienced weight loss
  - Abdominal echography shows a lesion in the body and tail region of the pancreas
- 

# Discussion Questions

---

**WHAT FURTHER HISTORY WOULD YOU LIKE TO KNOW?**

**WHAT TESTS OR EXAMINATIONS WOULD YOU CONDUCT?**

# Mrs. PC: Diagnostic Evaluation and Workup

---

## Labs

- CA 19-9: 2257 U/mL

## Imaging

- Abdominal CT scan pancreatic lesion of the body and tail
- PET: NO evidence of metastases

## Eco-endoscopy

- 4 cm diameter neoplasm attached to the splenic artery
- Pathology: adenocarcinoma

# Pancreatic Adenocarcinoma

---

- Fourth leading cause of cancer death in western countries
- Radical surgical resection is the only chance of cure but is feasible in only 10-20% of cases
- 5-year survival is rate is 25%, even in cases undergoing radical surgery
  - In these patients, local relapse occurs in 50% of cases and later onset metastases occurs in 70% of patients

# Mrs. PC: Surgery and Adjuvant Chemotherapy


---

- March, 2014: distal spleno-pancreatectomy + regional lymphadenectomy

## **Pathology**

- Adenocarcinoma, G3, with perivisceral adipose tissue , vascular and perineural infiltration
- Infiltration of the resection margin at the splenic artery
- 7 nodes were negative

## **Adjuvant chemo/radiotherapy**

- 6 courses of gemcitabine planned
  - Radiotherapy + concurrent capecitabine
- 


# Mrs. PC: Early Relapse

---

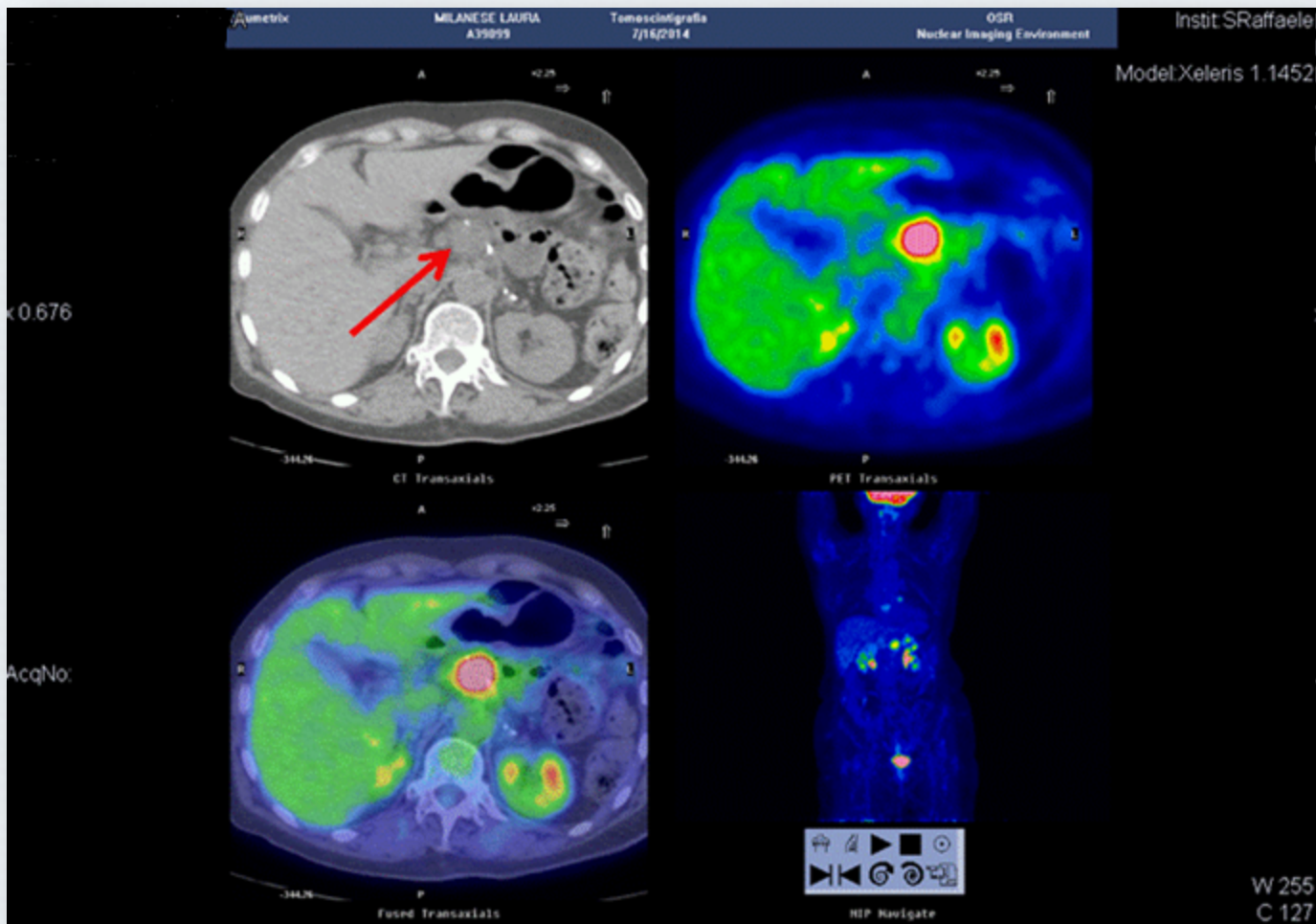
June, 2014: After two courses of gemcitabine:

- Admission for urinary infection

July, 2014: Abdominal pain

- Ecography shows 3 cm nodule in the pancreatic area
  - CA 19-9: 266 U/mL
  - CT and PET scan confirm relapse
- 

# Mrs. PC: Early Relapse CT PET Scan – July, 2014



Red arrow shows uptake in the celiac area



# Discussion Question

---



**WHAT TREATMENT STRATEGY  
WOULD YOU RECOMMEND?**

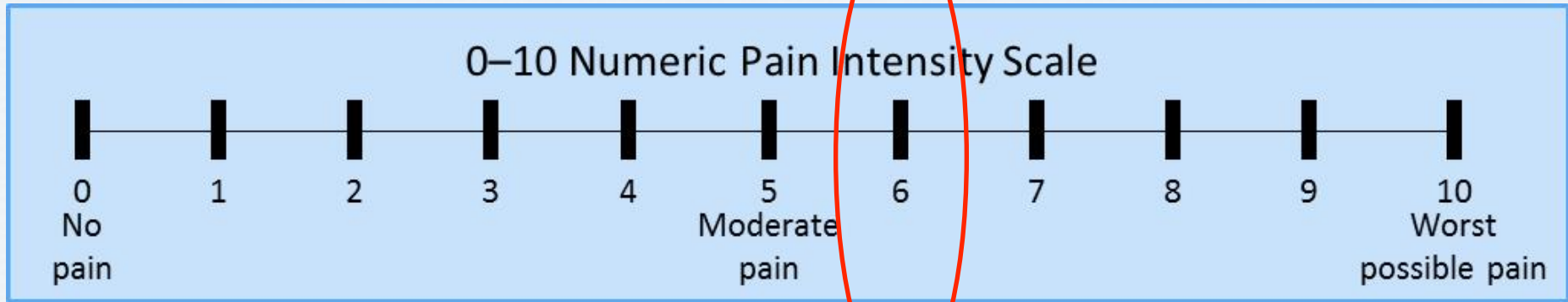
# Mrs. PC: Therapy at Relapse

---

- July, 2014: Multidisciplinary assessment
  - Palliative chemotherapy with capecitabine
  - Pain therapy : codeine and paracetamol 3 to 4 times a day .
- Pain is not well controlled (6/10) and constipation is worsened
- Palliative radiotherapy is planned

# Mrs. PC: Numeric Rating Scale (NRS) for Pain

---



**The patient's pain score is 6**

# Mrs. PC: Pain Consult at Palliative Care Outpatient Clinic

---

**18 August, 2014**

- Pain is reported in the upper mesogastric area
- Pain intensity fluctuates during the day
- Patient says the pain is often worsened when she lays on her back or eats
- Pain is severe, average pain is 6/10 with 8/10 episodes in the lumbar area with anterior belt-like radiation not well controlled by analgesic therapy
- Constipation is significant notwithstanding the use of laxatives
- Episodes of vomiting food are also occurring

# Pancreatic Cancer Pain

---

- Pain due to pancreatic cancer is usually referred to the upper mesogastric area right and left upper abdominal quadrants (30% of cases)
- Pain is often less well localized with diffused abdominal tenderness
  - In 60% of cases pain is referred to the back
- Pain is found 20% of cases at the onset of the disease
- Pain due to pancreatic head lesions is usually mesogastric pain due to cancer of the tail of the gland and is usually reported on the left side of the upper abdomen near to the rib cage
- The pain mechanism is **visceral nociceptive** but **somatic nociceptive** pain can occur due to retroperitoneal invasion of non-visceral structures

# Differential Diagnosis of Pancreatic Cancer Pain

Visceral Pain	Somatic Pain	Neuropathic Pain
<ul style="list-style-type: none"> <li>• Pancreatic gland infiltration pain</li> <li>• Gastric infiltration</li> <li>• Duodenal infiltration</li> <li>• Liver metastases: capsule distention, diaphragmatic irritation</li> <li>• Biliary tree distension</li> <li>• Bowel obstruction (duodenal, peritoneal carcinomatosis)</li> <li>• Ischemic abdominal pain due to mesenteric vessel involvement</li> </ul>	<ul style="list-style-type: none"> <li>• Retroperitoneal involvement (direct, nodal)</li> <li>• Parietal peritoneum and abdominal wall involvement</li> <li>• Abdominal distension due to ascites</li> <li>• Bone metastases</li> </ul>	<ul style="list-style-type: none"> <li>• Radiculopathy from retroperitoneal spread or bone metastatic involvement</li> <li>• Lumbosacral plexopathy</li> <li>• Epidural spinal cord compression</li> </ul>

Pain due to Cancer Therapies
<ul style="list-style-type: none"> <li>• Postoperative pain syndromes               <ul style="list-style-type: none"> <li>• Delayed gastric emptying</li> <li>• Wound dehiscence or non-healing</li> </ul> </li> <li>• Biliary prosthesis complications</li> <li>• Postchemotherapy pain syndromes</li> <li>• Liver chemoembolization</li> <li>• Mucositis</li> <li>• Postradiation pain syndromes</li> <li>• Radiation enteritis</li> </ul>

# Mrs. PC

---

Her pain is worsening pain; her pain therapy is rapidly adapted

- Transdermal fentanyl is titrated from 25 mcg/h to 200 mcg/hr
- Oral morphine solution 30 mg prn for titration and breakthrough pain management
- Ketorolac orally 15 mg/day
- Dexamethasone 4 mg
- At the same time, radiation therapy is administered (1-12/09)
- Supportive therapy with parenteral hydration antiemetics and analgesics is given in the palliative care outpatient clinic
- Pain intensity is 4/10

# Discussion Question

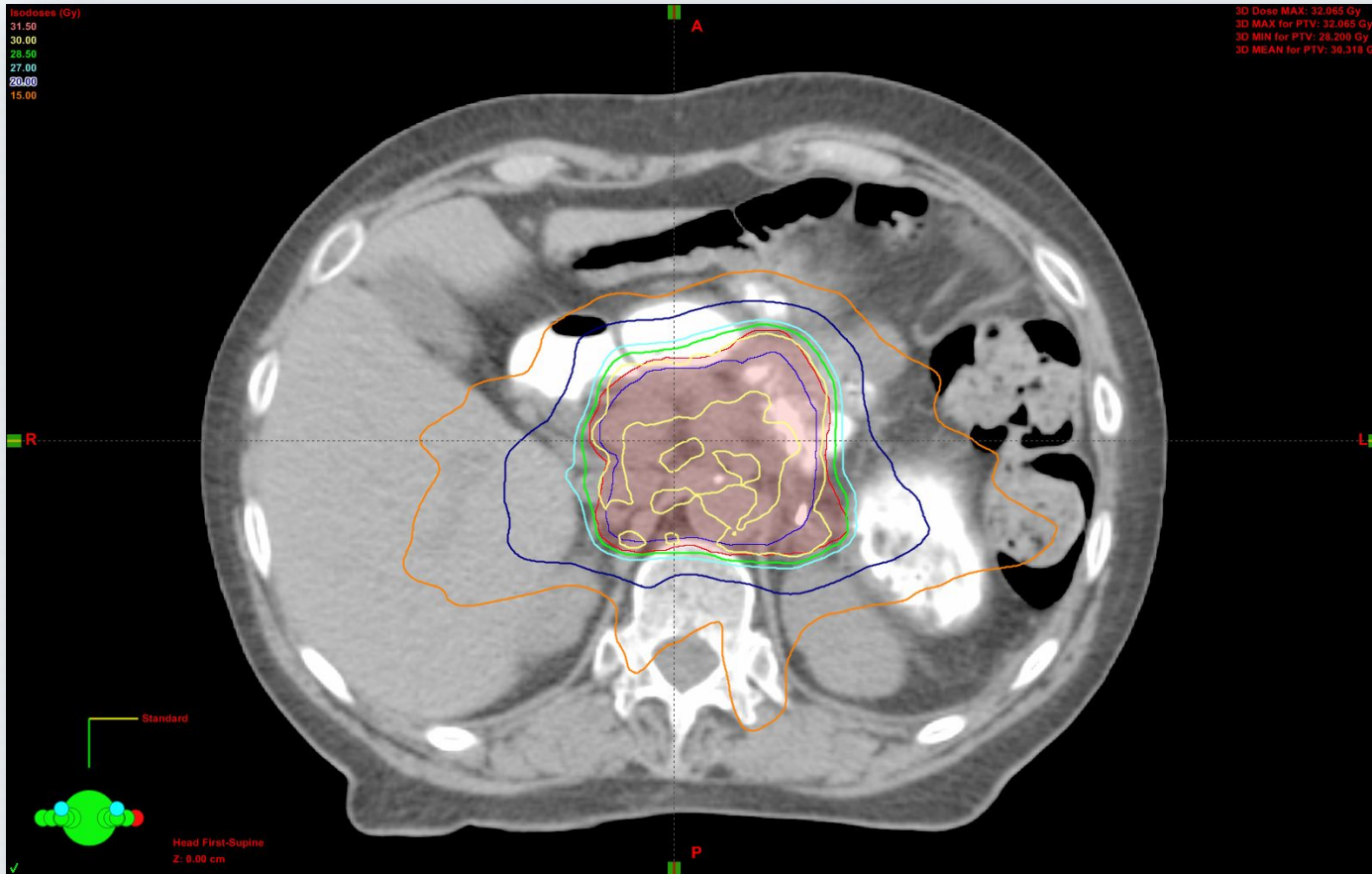
---



**WHAT TREATMENT STRATEGY  
WOULD YOU RECOMMEND?**



# Mrs. PC: Palliative Radiation Therapy Plan



01-12/09/2014 3 Gy/day (total = 30 Gy in 10 days)

# Mrs. PC: Pain Therapy after Radiation Therapy (RT)

---

- Two weeks after RT termination
  - Fentanyl TTS 150 mcg/h +
  - Oral morphine 20-30 mg /day +
  - Ketorolac 15 mg +
  - Antiemetics and laxative
- Six weeks after RT termination (pain improved)
  - Fentanyl TTS 100 mcg/h
  - Oral morphine and ketorolac discontinued
  - Can take food
  - Emesis and constipation have improved
  - Pain intensity = 3/10

# Mrs. PC: Follow Up

---

- Reduction of pain after radiation therapy for one month.
  - Pain worsens again in November 2014, and CT scan shows local disease progression
- Chest CT scan shows lung metastases
- New course of palliative chemotherapy with 5FU + FA

# Discussion Question

---



**WHAT TREATMENT STRATEGY  
WOULD YOU RECOMMEND?**

# Mrs. PC: Her Story Ends

---

## **November 2014 - February 2015**

- Attending palliative care outpatient clinic
- Pain intensity 4/10 with:
  - Fentanyl TTS dose progressively increased to 250 mcg/day
  - Oxycodone with paracetamol 20 mg every 8 hours
  - Ketorolac orally 15 prn 15 mg day

## **February 28 – March 8, 2015**

- Worsening of general conditions admitted to our palliative care home care program

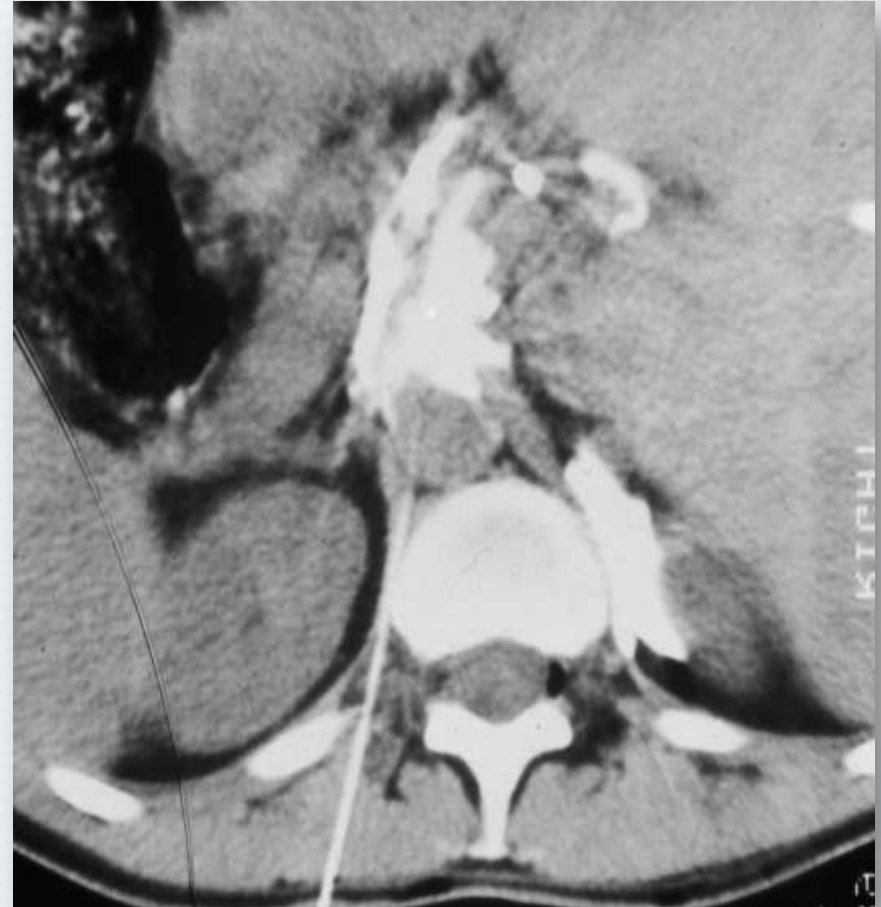
## **March 8, 2015**

- Subcutaneous morphine infusion 40 mg/24 hr + midazolam 15 mg/24 hour for delirium
- The patient dies at 11.30 AM the same day

# Alternative Analgesic Strategies

---

- If pain is due to visceral nociceptive stimulation (as was likely in the case of Mrs. PC) and is not well controlled by medications, celiac plexus alcoholization is a possibility as shown in the CT scan guided example on the right.
- In this example, a single needle paramedian right approach was used. The contrast medium shows the distribution of the neurolytic alcohol solution in the celiac area in front of the aorta.
- This technique was not used for Mrs. PC.



# References

---

- American Cancer Society. Opioid pain medicines. Available at: <http://www.cancer.org/treatment/treatmentsandsideeffects/physicalsideeffects/pain/paindiary/pain-control-opioid-pain-medicines>. Accessed February 23, 2015.
- Bal R, Diwan S, Gritsenko K. Pelvic pain. In: Benzon HT et al., eds. *Essential in Pain Medicine*. Third ed., Philadelphia, Elsevier Saunders, 2011. 378-85.
- Bouhassira D *et al.* Comparison of pain syndromes associated with nervous or somatic lesions and development of a new neuropathic pain diagnostic questionnaire (DN4). *Pain*. 2005; 114(1-2):29-36.
- Caraceni A, Hanks G, Kaasa S *et al.* Use of opioid analgesics in the treatment of cancer pain: evidence-based recommendations from the EAPC. *Lancet Oncol*. 2012;13(2):e58-68.
- Caraceni A, Portenoy RK. Pain management in patients with pancreatic carcinoma. *Cancer*. 1996;78(3 Suppl):639-53.
- Cleeland CS, Ryan KM. Pain assessment: global use of the Brief Pain Inventory. *Ann Acad Med Singapore*. 1994;23(2):129-38.
- Erdeck M, deLeon-Casasola OA. Neurolytic visceral sympathetic blocks. In: Benzon HT, *et al.*, eds. *Essential in Pain Medicine*. Third ed., Philadelphia, Elsevier Saunders, 2011. 525-30.
- Freyhagen R, Baron R. The evaluation of neuropathic components in low back pain. *Curr Pain Headache Rep*. 2009;13(3):185-90.
- Jensen TS *et al.* A new definition of neuropathic pain. *Pain*. 2011;152(10):2204-5.
- Julius D *et al.* In: McMahon SB, Koltzenburg M (eds). *Wall and Melzack's Textbook of Pain*. 5th ed. Elsevier; London, UK: 2006.
- Moreland LW, St Clair EW. The use of analgesics in the management of pain in rheumatic diseases. *Rheum Dis Clin North Am*. 1999;25(1):153-91.
- Portenoy RK. Treatment of cancer pain. *Lancet*. 2011;377(9784):2236-47.
- Ross E. Moving towards rational pharmacological management of pain with an improved classification system of pain. *Expert Opin Pharmacother*. 2001;2(1):1529-30.
- Webster LR. Breakthrough pain in the management of chronic persistent pain syndromes. *Am J Manag Care*. 2008;14(5 Suppl 1):S116-22.
- Woolf CJ. Central sensitization: implications for the diagnosis and treatment of pain. *Pain*. 2011;152(3 Suppl):S2-15.
- Yaksh TL, Wallace MS. In: Brunton L *et al.* (eds). *Goodman and Gilman's The Pharmacological Basis of Therapeutics*. 12th ed. (online version). McGraw-Hill; New York, NY: 2010.