

CLINICAL CASES

A decorative blue watercolor splash is located in the bottom right corner of the slide, blending into the light blue background.

Case 1: Mr. OA

A decorative blue watercolor splash is located in the bottom right corner of the slide.

Mr. OA: Case Presentation

- 62-year-old lawyer
 - Mild left knee pain for 3 month, but became worse 1 week ago
 - No swelling
 - 1 week earlier: 2-hour walk in the countryside 2 days in a row
 - Walks 3–4 times a week
 - No current medications
- 

Mr. OA: Discussion Question

**WHAT ARE SOME POSSIBLE
CAUSES OF MR. OA'S
JOINT PAIN?
WHAT ADDITIONAL
INFORMATION WOULD YOU
LIKE TO KNOW?**

Mr. OA: Pain History

- Where is the pain?
 - Diffuse but more pronounced medially
- Trigger:
 - Walk in the country, 2 hours, 2 days in a row
 - Morning stiffness that disappears after 30 minutes
- Swelling:
 - Not this time, but appears when he is more active
 - No locking or buckling
- Old surgery or deformation:
 - Medial meniscectomy of left knee 37 years ago

Mr. OA: Discussion Question



**BASED ON THE INFORMATION
COLLECTED, WHAT WOULD YOU
LOOK FOR ON THE PHYSICAL EXAM?**

Mr. OA: Targeted Examination

- Inspection:
 - Slight limp
 - Overweight
 - Mild genu varum
 - No swelling, atrophy or redness
- Mr. OA locates his pain with his hand in the anterior medial area of the knee
- Incomplete flexion on the affected side

Mr. OA: Targeted Examination (cont'd)

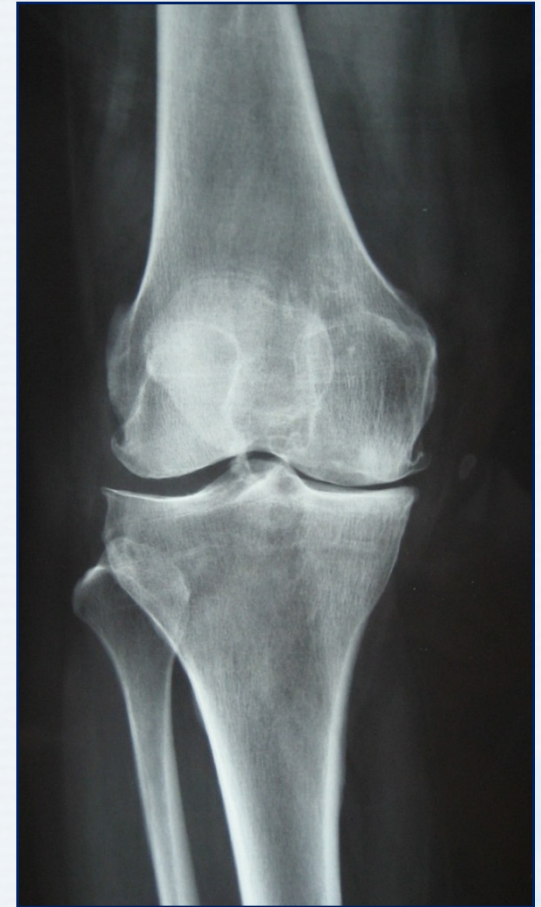- Range of motion:
 - Incomplete flexion on the affected side
 - Normal extension
- Swelling:
 - Patellar tap: negative
 - Therefore, no effusion
- Palpation:
 - Medial joint-line tenderness, no pain elsewhere
 - Crepitus was detected in the left knee
- Hip examination: normal

Mr. OA: Discussion Question

**WOULD YOU CONDUCT ANY
FURTHER INVESTIGATIONS SUCH
AS LABORATORY TESTS
OR IMAGING?**

Mr. OA: Investigation

- X-ray of knee shows:
 - Multiple moderate osteophytes
 - Definite medial joint space narrowing
 - Some sclerosis



Mr. OA: Discussion Question

WHAT WOULD BE YOUR DIAGNOSIS?

Mr. OA: Diagnosis

- Osteoarthritis of the knee
(medial compartment)

Mr. OA: Discussion Question



**WHAT WOULD BE YOUR
TREATMENT PLAN?**


Mr. OA: Treatment Plan

- Apply heat on local pain area
- Physiotherapy or therapeutic exercise
- Possibility of joint injection
- Acetaminophen
- nsNSAIDs/coxibs

Case 2: Mrs. RA

A decorative blue watercolor splash is located in the bottom right corner of the slide.

Mrs. RA: Case Presentation

- 55-year-old legal secretary
 - Complains that she has had pain and swelling of several hand joints for about 2 years, but these have become worse in the last 3 months
 - Her joint pain and swelling is more severe in the morning and she has difficulty typing, but her symptoms get better in the afternoon
 - She asks to be put on same medication as her husband who has osteoarthritis
- 

Mrs. RA: Discussion Question




**WHAT ADDITIONAL INFORMATION WOULD
YOU LIKE TO KNOW?**

Physical Examination

- Her hand joints are swollen and tender, involving PIP and MCP
- Slight swelling and tender in both wrist
- Symmetrical in both hands

Mrs. RA: Discussion Question



**WOULD YOU CONDUCT ANY FURTHER
INVESTIGATIONS SUCH AS LABORATORY
TESTS OR IMAGING?**

X-ray and Abnormal Lab Findings

- Osteoporosis around PIP joints and erosion of some PIP joints
- Her blood ESR and CRP were elevated
- Her RF and anti-CCP antibody are positive

Mrs. RA: Discussion Question



WHAT WOULD YOU TELL MRS. RA?

What Mrs. RA's diagnosis?

- Her diagnosis is rheumatoid arthritis

Mrs. RA: Discussion Questions

**WHAT WOULD BE YOUR GOALS
FOR MRS. RA?
WHAT WOULD BE YOUR
TREATMENT PLAN?**


Mrs. RA: Treatment Plan

- You prescribe nsNSAID/coxib to manage the pain from the acute flare
- Refer Mrs. RA to rheumatologist to confirm diagnosis and initiate disease-modifying treatment

Case Template

A decorative blue watercolor splash is located in the bottom right corner of the slide, blending into the light blue background.

Patient Profile

- Gender: **male/female**
 - Age: **#** years
 - Occupation: *Enter occupation*
 - Current symptoms: *Describe current symptoms*
- 
- A decorative blue watercolor splash is located in the bottom right corner of the slide, extending from the bottom edge and slightly up the right side.

Medical History

Comorbidities

- *List comorbidities*

Measurements

- BMI: # kg/m²
- BP: #/# mmHg
- *List other notable results of physical examination and laboratory tests*

Social and Work History

- *Describe any relevant social and/or work history*

Current medications

- *List current medications*


Discussion Questions

**BASED ON THE CASE PRESENTATION, WHAT
WOULD YOU CONSIDER IN YOUR
DIFFERENTIAL DIAGNOSIS?**

**WHAT FURTHER HISTORY WOULD YOU LIKE
TO KNOW?**

**WHAT TESTS OR EXAMINATIONS WOULD
YOU CONDUCT?**

Pain History

- Duration: *When did pain begin?*
 - Frequency: *How frequent is pain?*
 - Quality: *List descriptors of pain*
 - Intensity: *Using VAS or other tool*
 - Distribution and location of pain: *Where does it hurt?*
 - Extent of interference with daily activities: *How does pain affect function?*
- 

Clinical Examination

- *List results of clinical examination*

Results of Further Tests and Examinations

- *List test results, if applicable*

Discussion Question

**WHAT WOULD BE YOUR
DIAGNOSIS FOR THIS PATIENT?**

Diagnosis

- *Describe diagnosis*

Discussion Question

**WHAT TREATMENT STRATEGY
WOULD YOU RECOMMEND?**

Treatment Plan

- *List both pharmacologic and non-pharmacologic components of management strategy*

Follow-up and Response to Treatment(s)

- *Describe pain, function, adverse effects, etc. at next visit*

Case Template: Discussion Question



**WOULD YOU MAKE ANY CHANGES
TO THERAPY OR CONDUCT
FURTHER INVESTIGATIONS?**

Other Investigations

- *List results of further investigations, if applicable*

Changes to Treatment

- *Outline changes to therapy, if applicable*

Conclusion

- *Describe pain, function, adverse effects, etc. at next visit*

What If Scenarios

- How would your diagnosis/treatment strategy change if...
 - *List what if scenarios*