
CLINICAL CASES

A decorative blue watercolor splash is located in the bottom right corner of the slide, blending into the light blue background.

Case: Mr. LBP

A decorative blue watercolor splash is located in the bottom right corner of the slide, blending into the light blue background.

Mr. LBP: Case Presentation


- Mr. LBP is a 35-year-old male
- He fell down while participating in a recreational sports activity
 - He subsequently developed low back pain
- Upon arrival at your office, Mr. LBP rates his pain intensity at 8 on the 10-point VAS
- He has no previous history of lower back pain
- He has no comorbidities

Mr. LBP: Discussion Questions

**WHAT WOULD YOU LOOK FOR ON
THE PHYSICAL EXAM?**

**WHAT ARE THE RED FLAGS THAT
SHOULD TRIGGER REFERRAL OR
FURTHER INVESTIGATION?**

Mr. LBP: Physical Exam

- Upon physical exam, you notice Mr. LBP is limping
 - He is also experiencing paralumbar muscle spasms
 - There are no neurological findings
 - Mr. LBP displays limited trunk flexion/extension
- 
- A decorative blue watercolor splash is located in the bottom right corner of the slide, extending from the bottom edge and slightly towards the left.

Mr. LBP: Discussion Question



**WHAT OTHER INVESTIGATIONS
WOULD YOU PERFORM?**

Mr. LBP: Imaging


- The following imaging tests were performed on Mr. LBP:
 - Lumbar X-rays
 - CT scan
 - MRI

Mr. LBP: Discussion Questions

**WHAT WOULD BE YOUR
MANAGEMENT PLAN FOR
MR. LBP?**

**WHAT APPROACH WOULD YOU
USE TO CONTROL
MR. LBP'S PAIN?**


Mr. LBP: Discussion Questions

- How soon would you see Mr. LBP again?
 - What would you do at the second visit?
 - How would you determine if Mr. LBP is at risk for chronic pain?
 - When would you consider referring Mr. LBP to a specialist?
- 
- A decorative blue watercolor splash is located in the bottom right corner of the slide, extending from the bottom edge and slightly up the right side.

Case: Mr. MP

A decorative blue watercolor splash is located in the bottom right corner of the slide, blending into the light blue background.

Mr. MP: Case Presentation

- Mr. MP is a 45-year-old male construction worker
 - Upon arrival at your office, he complains of lower back pain that radiates into his left leg
 - He says the pain has been present for “a couple of years”
 - He also tells you he is sleeping badly and is feeling anxious
- 

Mr. MP: Discussion Question

**WHAT ADDITIONAL INFORMATION WOULD
YOU LIKE TO KNOW ABOUT MR. MP
AND HIS PAIN?**

Mr. MP: Pain History

- Mr. MP was healthy until he suffered a work-related accident 4 years ago
 - The accident resulted in disc herniation at L5-S1
 - Mr. MP has been unable to work since that time
- Surgical intervention was unsuccessful
- In the past he took NSAIDs for the pain
 - However, he discontinued most of these medications within 1 week because he felt they “did not work”

Mr. MP: Description of Pain

- Mr. MP describes his pain as “burning,” “electric shocks” and “numbness”
- He rates his pain between 60 and 80 on the 100-point VAS
- He tells you the pain is located in his lower back and radiates into his left leg
- He also tells you that the pain is aggravated by physical movement

Mr. MP: Discussion Questions

**HOW DO YOU THINK MR. MP'S PAIN
IS AFFECTING HIM?**

**WHAT FACTORS WOULD YOU
CONSIDER WHEN EVALUATING
MR. MP'S SLEEP PROBLEMS?**

**WHAT FACTORS WOULD YOU
CONSIDER WHEN EVALUATING
MR. MP'S MOOD?**

Mr. MP: Sleep Disturbances

- Mr. MP complains of night-time awakenings due to paroxysms of pain

Mr. MP: Mood

- Mr. MP reports the pain is making his life “unbearable”
- He is also feeling loss of pride because he cannot work
- Mr. MP feels something radical needs to be done
- He seems irritable and displays a somewhat aggressive attitude
- You administer the Hamilton Rating Scale for Depression and the Hamilton Anxiety Rating Scale. His scores are:
 - Depression score = 15*
 - Anxiety score = 13†


*A score of <17 indicates mild severity

†A score of 0–7 is generally accepted to be within the normal range

Mr. MP: Discussion Question

**BASED ON THE INFORMATION PROVIDED
SO FAR, WHAT WOULD YOU LOOK FOR ON
MR. MP'S PHYSICAL EXAM?**

Mr. MP: Physical Examination

- Mr. MP experiences pain at the S1 level on physical exam
 - There are no visible abnormalities at the old surgical wound sites
 - Upon examination of Mr. MP's back you find muscular atrophy
 - On his left leg, Mr. MP displays hypoesthesia to touch or pricking and allodynia in a radicular distribution that is evoked by light brushing
 - The straight-leg raise (Lasègue sign) is positive for Mr. MP's left leg
- 

Mr. MP: Discussion Question

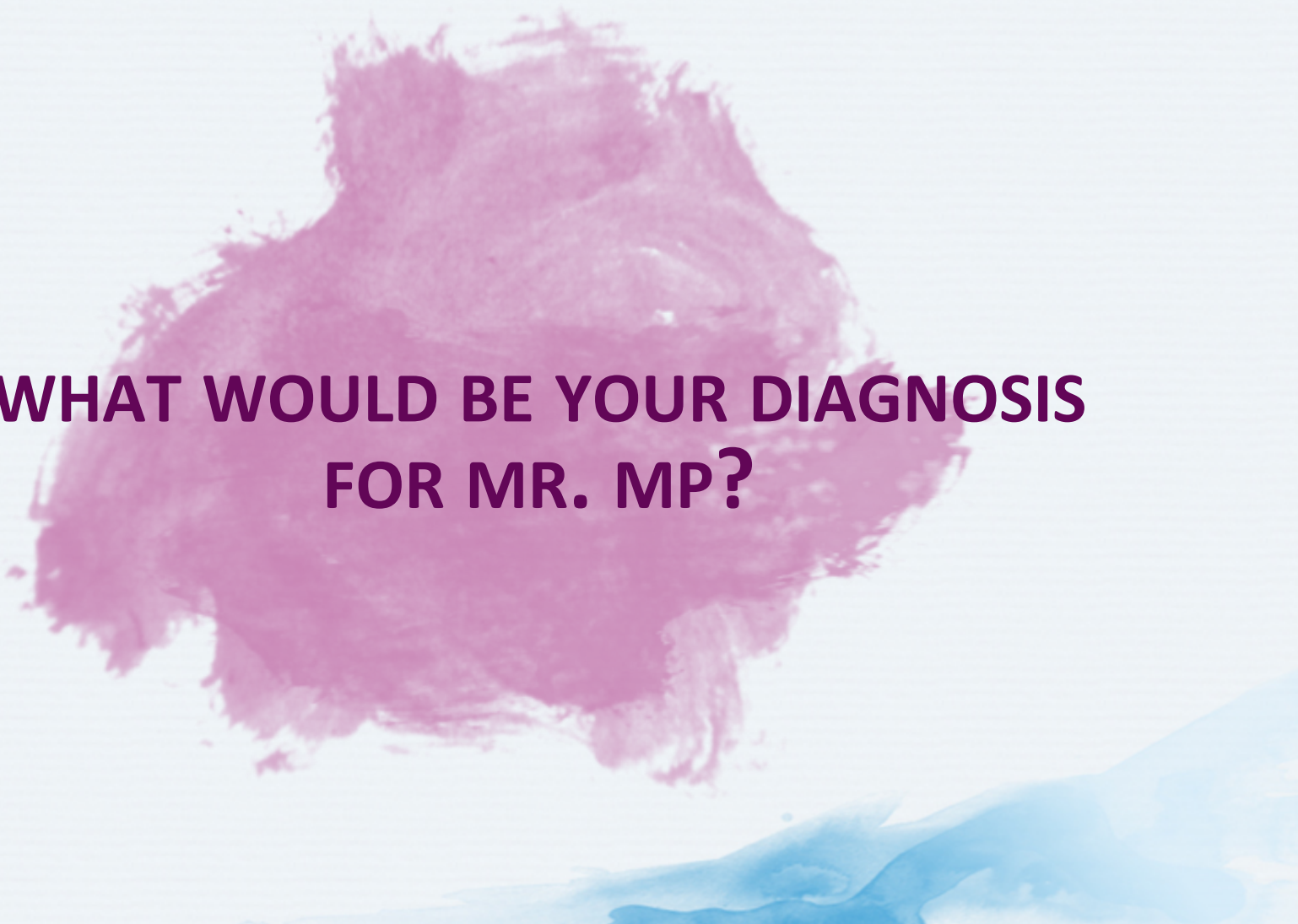


**WHAT FURTHER INVESTIGATIONS WOULD
YOU CONDUCT TO DETERMINE A
DIAGNOSIS FOR MR. MP?**

Mr. MP: Other Investigations

- Gadolinium-enhanced magnetic resonance imaging confirmed Mr. MP has a herniated L5–S1 disc with fibrosis
 - Other conditions were ruled out
- Changes compatible with chronic S1 radiculopathy were revealed by electromyography of Mr. MP's left leg
- Mr. MP's laboratory tests were normal

Mr. MP: Discussion Question



**WHAT WOULD BE YOUR DIAGNOSIS
FOR MR. MP?**

Mr. MP: Diagnosis

- Previous surgical intervention (back surgery) was unsuccessful
- Mr. MP is diagnosed with chronic low back pain
 - His low back pain is classified as *mixed pain*, with both a *neuropathic component* (radicular pain) and a *nociceptive component*

Mr. MP: Discussion Questions


WHAT MANAGEMENT PLAN WOULD YOU ESTABLISH FOR MR. MP?

BASED ON THE DIAGNOSIS OF MIXED LOW BACK PAIN, WHAT CLASSES OF MEDICATION WOULD YOU RECOMMEND TO HELP MANAGE MR. MP'S PAIN?

HOW WOULD MR. MP'S SLEEP AND PSYCHIATRIC COMORBIDITIES AFFECT YOUR MANAGEMENT OF HIS PAIN?

Mr. MP:

Non-pharmacological Management

- You provide Mr. MP with information on low back pain, self-management and on how to pace his activities
 - You also recommend physiotherapy, such as hydrotherapy, aerobic exercise and core muscle strengthening
 - You refer Mr. MP to a clinical psychologist for management of his psychiatric comorbidities
- 

Mr. MP:

Pharmacologic Management

- Mr. MP is prescribed:
 - An $\alpha_2\delta$ ligand to manage the neuropathic pain component of his pain
 - A weak opioid to manage both the nociceptive and neuropathic components of his pain
 - An SNRI to help manage his symptoms of depression

Mr. MP: Follow-Up

- One month later, Mr. MP is still experiencing the same intensity of pain according to the 100-point VAS:
 - He rates his pain as 60 at the best of moments and 80–90 at the worst


Mr. MP: Discussion Question

- You know adherence to medications has been an issue for Mr. MP in the past. How would you determine if he is adherent to his current pharmacotherapy?

Mr. MP: Determining Adherence

- When you ask Mr. MP how he is doing with his medications he says he does not think they are working
 - Upon further questioning, it becomes clear Mr. MP stopped taking the medications after 6 days

Mr. MP: Improving Adherence

- You explain in simple terms the medications might take a while to have an effect
 - You give him handouts to take home so he can read about his condition
 - You suggest he set an alarm on his phone to remind him to take his medications every day
- 
- A decorative blue watercolor splash is located in the bottom right corner of the slide, extending from the bottom edge and slightly up the right side.


Mr. MP: Conclusion of Case

- One month later, although Mr. MP is still experiencing pain, it is no longer a constant complaint and Mr. MP's activity/function has improved
- Mr. MP rates his pain intensity between 40–60 on the 100-point VAS
- Mr. MP's anxiety and depression have been reduced and he has started sleeping for progressively longer periods during the night

Case Template

A decorative blue watercolor splash is located in the bottom right corner of the slide, blending into the light blue background.

Patient Profile

- Gender: **male/female**
 - Age: **#** years
 - Occupation: *Enter occupation*
 - Current symptoms: *Describe current symptoms*
- 
- A decorative blue watercolor splash is located in the bottom right corner of the slide, extending from the bottom edge and slightly towards the left.

Medical History

Comorbidities

- *List comorbidities*

Measurements

- BMI: # kg/m²
- BP: #/# mmHg
- *List other notable results of physical examination and laboratory tests*

Social and Work History

- *Describe any relevant social and/or work history*

Current medications

- *List current medications*


Discussion Questions

**BASED ON THE CASE PRESENTATION,
WHAT WOULD YOU CONSIDER IN YOUR
DIFFERENTIAL DIAGNOSIS?**

**WHAT FURTHER HISTORY WOULD YOU
LIKE TO KNOW?**

**WHAT TESTS OR EXAMINATIONS
WOULD YOU CONDUCT?**

Pain History

- Duration: *When did pain begin?*
 - Frequency: *How frequent is pain?*
 - Quality: *List descriptors of pain*
 - Intensity: *Using VAS or other tool*
 - Distribution and location of pain: *Where does it hurt?*
 - Extent of interference with daily activities: *How does pain affect function?*
- 

Clinical Examination

- *List results of clinical examination*

Results of Further Tests and Examinations

- *List test results, if applicable*

Discussion Question

**WHAT WOULD BE YOUR
DIAGNOSIS FOR THIS PATIENT?**

Diagnosis

- *Describe diagnosis*

Discussion Question

**WHAT TREATMENT STRATEGY
WOULD YOU RECOMMEND?**

Treatment Plan

- *List both pharmacologic and non-pharmacologic components of management strategy*

Follow-up and Response to Treatment(s)

- *Describe pain, function, adverse effects, etc. at next visit*

Case Template: Discussion Question



**WOULD YOU MAKE ANY CHANGES TO
THERAPY OR CONDUCT FURTHER
INVESTIGATIONS?**

Other Investigations

- *List results of further investigations, if applicable*

Changes to Treatment

- *Outline changes to therapy, if applicable*

Conclusion

- *Describe pain, function, adverse effects, etc. at next visit*


What If Scenarios

- How would your diagnosis/treatment strategy change if...
 - *List what if scenarios*

Additional Clinical Case

MR. A

Mr. A: Patient Details and Initial Presentation

- 30-year-old male, soldier in the army
 - Presented to the emergency room complaining of sudden onset of low back pain following a military training exercise
 - He cannot stand or sit without pain, which also radiates to the left leg
 - He is not able to sleep because of this severe pain
- 

Mr. A: Discussion Question



**WHAT ADDITIONAL
INFORMATION WOULD YOU
LIKE TO KNOW?**

Mr. A: Medical History


- Back pain described as initially being “dull, heavy pressure” and rated as 7/10 on the VAS
- Later patient experienced “tingling” and “numbness” in the left leg and foot associated with intense pain in the left buttock and thigh
 - Described as sometimes being an excruciating “electric shock-like” and “burning” sensation
- Also experienced sudden motor weakness in his left leg with exacerbation of his back pain

Mr. A: Discussion Question

A large, irregular blue watercolor splash is centered behind the text. It has various shades of blue, from light to dark, with some white areas where the paint didn't reach. There are also some smaller, darker blue spots and streaks extending from the main splash.

**BASED ON THE INFORMATION
COLLECTED, WHAT WOULD YOU
LOOK FOR ON THE PHYSICAL EXAM?**

Mr. A: Physical Examination

- Reduced sensitivity to light touch (tactile hypoesthesia) over the side of the left leg and foot
 - Laségue sign positive at $\sim 30^\circ$
 - Diminished reflexes
 - Positive spring test: reproduction of axial back pain with direct pressure over the suspect spinous process
- 

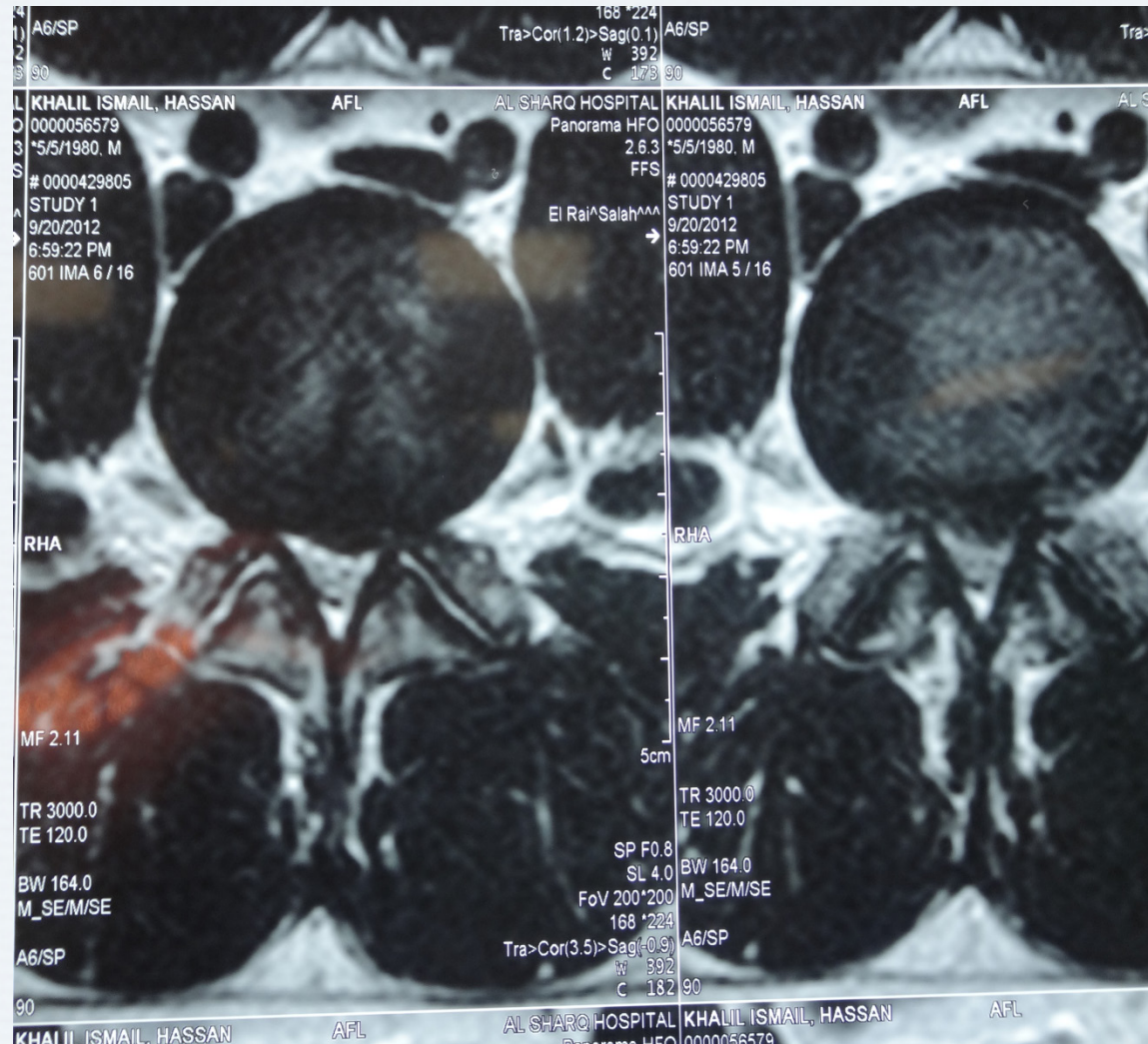
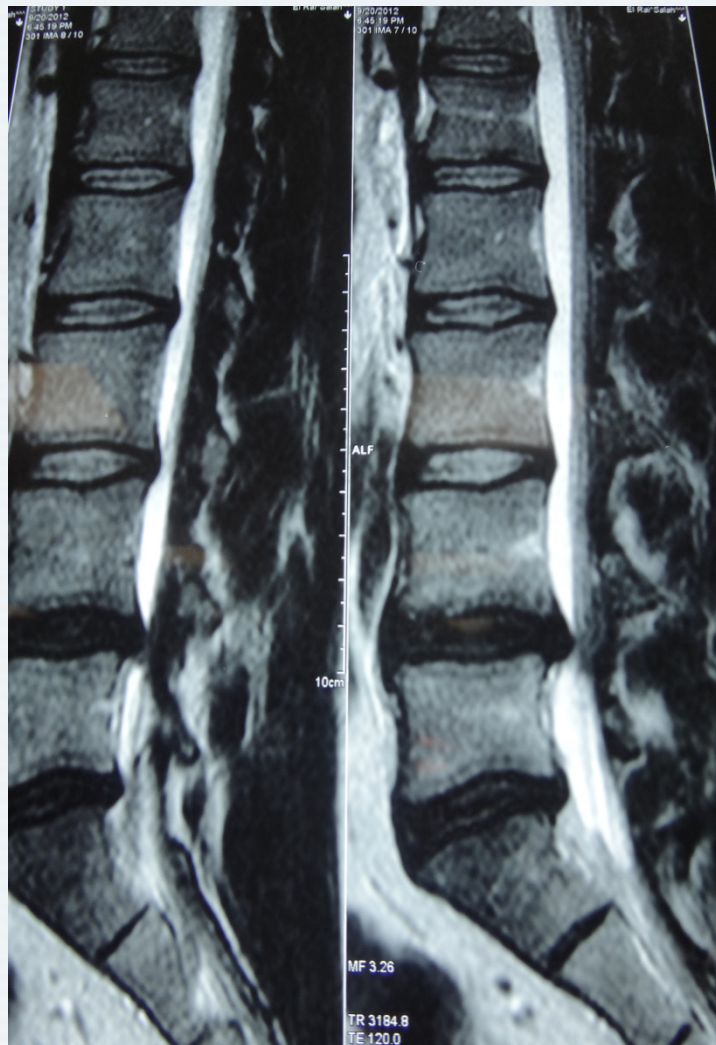
Mr. A: Discussion Question

**WHAT IMAGING OR LABORATORY
TESTS WOULD YOU ORDER?**

Mr. A: Investigations

- Plain X-ray of spine
- MRI
- EMG

Mr. A: MRI Results



Mr. A: Discussion Question

**BASED ON THE MRI RESULTS, WHAT WOULD
BE YOUR NEXT STEPS?**

Mr. A: Action Plan

- Herniated disc at the L4–L5 space was confirmed by MRI
 - Patient was submitted to surgery
- 
- A decorative blue watercolor splash is located in the bottom right corner of the slide, extending from the bottom edge and slightly towards the right edge.


Mr. A: Post-operative Pain Management

- Immediately after surgery:
 - Acetaminophen 1g IV/6 hours
 - IV coxib
 - IV opioid, adjusted according to VAS
- Sedation score was assessed
- Patient-controlled analgesia started in the PACU
 - No continuous rate


Mr. A: Post-operative Pain Management (cont'd)

- Patient-controlled analgesia was continued for 48 hours along with:
 - Acetaminophen 1g/6 hours
 - IV coxib
- Patient-controlled analgesia discontinued after 48 hours and relayed with oral opioid

Mr. A: Results of Surgery

- Anatomical results of the surgery were considered to be very satisfactory
 - Patient experienced a significant reduction in radicular pain and sensory loss
 - However, there was limited reduction in back pain, which increased progressively
- 
- A decorative blue watercolor splash is located in the bottom right corner of the slide, extending from the bottom edge and slightly up the right side.

Mr. A: Follow-Up

- Persistent back pain 6 months after surgery
 - Mainly lumbar pain, but occasionally electric-type pain in the same leg
- 
- A decorative blue watercolor splash is located in the bottom right corner of the slide, extending from the right edge and slightly upwards.

Mr. A: Discussion Questions



**HOW WOULD YOU ASSESS
MR. A'S PAIN?**

**WHAT ELSE WOULD YOU LIKE
TO KNOW?**

Mr. A: Pain Assessment

DN4 questionnaire resulted in a score of 5/10, indicating the presence of neuropathic pain.

Q1 Does the pain have one or more of the following Characteristics:

1. Burning?
2. Painful cold?
3. Electric shocks?



Q2 Is the pain associated with one or more of the following symptoms in the same area:

4. Tingling?
5. Pins and needles?
6. Numbness?
7. Itching?



Q3 Is the pain localised in an area where the examination may reveal one or more of the following characteristics?

8. Hypoaesthesia to touch?
9. Hypoaesthesia to pinprick?



Q4 In the painful area, can the pain be caused or increased by:


10. Burning?




Yes = 1 point
No = 0 points

Patient score: 5/10

Mr. A: Comorbid Symptoms

- Major sleep disturbance
 - Increasing feelings of isolation and depression
 - Long duration of sick leave and delayed job promotions
- 
- A decorative blue watercolor splash is located in the bottom right corner of the slide, extending from the bottom edge and slightly up the right side.

Mr. A: Depression and Anxiety

- Depressive and anxiety symptoms as scored by the Hamilton Rating Scales:
 - Anxiety score of 13
 - Depression score of 15
- 

Mr. A: Discussion Question

**BASED ONLY ON THE CLINICAL HISTORY
AND PHYSICAL EXAMINATION,
WHAT WOULD BE THE MOST
PROBABLE DIAGNOSIS?**

Mr. A: Diagnosis


- Patient has lumbar radiculopathy

Mr. A: Discussion Question



**WHAT ARE THE ELEMENTS THAT
SUPPORT YOUR DIAGNOSIS?**

Mr. A: Diagnosis

- Diagnosis was based on:
 - History of disc herniation with lumbar pain and surgery (failed to relieve the pain completely)
 - Verbal descriptors and sensory changes suggesting nerve involvement
 - Topographical distribution of pain and sensory changes (L4/L5)
 - Pain refractory to conventional analgesics
- 

Mr. A: Discussion Question

**WHAT OTHER ELEMENTS OR
EXAMS/TESTS DO YOU NEED TO
CONFIRM THE DIAGNOSIS?**

Mr. A: Other Examinations

- Imaging did not show recurrence of disc herniation
- Somatosensory evoked potentials were normal
- EMG showed denervation in the L5 territory

Mr.A: Previous Pain Treatments and Outcomes

- nsNSAID therapy
 - Proved ineffective
- Local infiltration with lidocaine
 - Initially provided satisfactory relief of lumbar pain and paraspinal muscle spasm, but the duration of effect shortened over time
- Acetaminophen and tramadol
 - Proved ineffective
- Opioids
 - Induced a significant reduction in lumbar pain but only a slight improvement in radicular burning pain
 - Opioid treatment was discontinued because of adverse events including nausea, constipation and somnolence.

Mr. A: Discussion Question



**WHAT WOULD BE YOUR
TREATMENT PLAN?**

Mr. A: Treatment and Outcome

- Treatment with TCA
 - Induced some reduction in burning pain
- $\alpha_2\delta$ ligand was added
 - Induced a further decrease in burning pain
 - Reduced the percentage of pain paroxysms
 - Treated his sleep disturbances